



ISSN: 0067-2904

## Effect of Different Concentration of Super Cyren Pesticide on Some Physiological and Histological Traits of Mice After Different Periods of Oral Administration

Sahah A. Hameid A. Rahman\*, Dalal A. Sattar

Department of Biology, College of Science, Al-Mustansiriyah University, Baghdad, Iraq.

### Abstract

This study aims to determine the toxic effect for different concentrations of supercyren pesticide on some physiological and histological features of the sixty male mice by oral administration. The experimental mice took oral administration of 5mg and 10mg/Kg every day to every mice for two weeks in group 2 and 3 respectively and for four weeks for group 5 and 6 respectively. After 2 or 4 weeks AST, ALT and ALP enzymes, urea, creatinine and testosterone hormone were estimated. The following organs were taken for histological studies (Liver, Kidney, testes). The results of this physiological study showed that the oral administration of supercyren pesticide affect these organs (Kidney, liver, testes). Then histological changes in kidney, liver and testes proved the physiological effect. On the other hand, the high concentration of the pesticide had a significant impact on users as well as the greater duration effect was greater physiological and histologically.

**Keywords:** super cyren pesticide, Liver, Kidney, testes, histological and physiological features.

## تأثير تركيزات مختلفة من مبيد السوبركايرين على بعض الصفات الفسيولوجية والهستولوجية للفئران بعد فترات مختلفة من أخذها بالفم

صباح عبد الحميد عبد الرحمن\*، دلال عبد الستار

قسم علوم الحياة، كلية العلوم، الجامعة المستنصرية، بغداد، العراق.

### الخلاصة

هذه الدراسة تهدف إلى تحديد التأثير السمي للتركيزات المختلفة من مبيد السوبركايرين على بعض الخصائص الفسيولوجية والهستولوجية لستون ذكر من الفئران المأخوذ عن طريق الفم وبتراكيزين 5ملغم و10 ملغم لكل كغم وزن يأخذها كل يوم ولكل فأر لمدة اسبوعين للمجموعة ALT-ASTالثانية والثالثة ولمدة اربعة اسابيع للمجموعتين الخامسة والسادسة وتم قياس واليوريا والكرياتينين و هرمون التستوستيرون واخذت مقاطع هستولوجية من الاعضاء التالية ( الكبد، الكلية، الخصية ) وكانت النتائج تشير الى النتائج على انسجة هذه الاعضاء وكذلك تأثر هذه الاعضاء فسيولوجيا وهذا يدعم تاثر نسيجها وان التركيز الأعلى كان له تأثير معنوي اكبر على هذه الاعضاء فسيولوجيا وهستولوجيا

### Introduction

Most pesticides specially the phosphorus insecticide group, were recognized by its higher lipophilic ability and it is easily absorbed by the body of living microorganisms [1]. Pesticide affects the biochemical metabolism in mammals and aquatic organisms especially during the past two decades,

\*Email: Sabah.abdalhamid@yahoo.com

the wide spread use of pesticides has led to the contamination of the environment . The adverse effects on plants and wild life has similar toxic effect on man because they are eating the same contaminated food snuffs [2].

All pesticides undergo different serious biochemical changes inside the living organism's body either it was aquatic animals or mammals. The study of pesticides metabolism is considered very important, because the metabolic products of these pesticides are toxic [1] .This process depends on hepatic microsomal enzymes which perform hydrolysis. Our study focuses on the toxic effect of different concentrations of organophosphorous pesticide called Chlorpyrphous, some histological and physiological features of the internal organs of (*Mus musculus*) mice by oral administration. The histological studies were carried out on the liver and kidney. The results of this study showed that the oral administration of chloropyrphose resulted in some histological changes in the kidney and liver in addition to elevation in the level of GOT of GPT enzyme, urea and protein [3].

In mammals like humans, mice, rats and dogs the pesticides show an obvious physiological and metabolic effects on them [4]. The results of the present oral and IV titanium dioxide study indicates very low oral bioavailability and slow tissue elimination. Limited uptake in combination with slow elimination might result in the long run in potential tissue accumulation [5].

Liver is a vital organ that has many important metabolic activities, it plays a key role in metabolism of carbohydrates, lipids and proteins. It also stores many substances that include iron, glycogen and vitamins (A, D and B12) [6] . AST, ALT, ALP are enzymes released during any injury to liver cells or bile duct. liver tests can be used to screen for liver disease [7] and [8] . Kidneys maintain homeostasis by removing metabolic wastes from blood and produce urine to excrete them , they also help regulating red blood cells production, blood volume and blood pressure in addition to composition, volume and pH of body fluids [9] . Also, Testes produce the testosterone hormone and responsible for secondary sexual characteristics of male. Because of the great role of these organs (liver, kidney and testes) we decided to carry out this experiment on these vital organs . The aim of this study is to determinate the toxic effect for different concentrations of supercyren pesticide on histological and physiological features of liver , kidney and testes of male mice and their effect on Urea , Creatinine , Liver enzymes (AST, ALT and ALP) and Testosterone hormone by oral administration .

### Materials and Methods

Sixty male adult albino rats weighed about (20-30 gm) were housed in separated cages in the animal house of the college of science/ Al-Mustansiriyah University under temperature ( $25\pm 2$  °C), water and food used in the diet of *ad libitum* rats to give maximum care, at (December, 2016-January, 2017)..

In this experiment we used different concentration of organophosphorous pesticide called supercyren EC (Active substances in pesticide chlorpyrifos 500 g/L and cypermethrin 50 g/L), Insecticide has great potency and comprehensive use to combat harmful insects . The mechanism of this pesticide is unknown precisely but it affects the liver and kidney in addition to blood vessels which leads to cirrhosis of the liver and damage of kidneys, the fatal dose of this pesticide is 25 mg/Kg body [10] . These animals were divided randomly into six groups each group consist of ten male rates each. Group 1 untreated (control) , group 2 were given orally administrated supercyren ( technical grade 10% supercyren dissolved in distilled water 90%) daily at dose of 5 mg/Kg to every mouse for two weeks , group 3 were given orally administrated supercyren (technical grade 10% dissolved in distilled water 90%) given daily at dose of 10 mg/Kg body weight to every mouse for two weeks also. Groups 1, 2, 3 were scarified by after 2 weeks of experiment. Group 4 untreated (for control) , group 5 were given supercyren pesticide at dose 5 mg/Kg., group 6 were given supercyren by oral administration at dose of 10 mg/Kg daily for four weeks. Group 4,5, and 6 were scarified by after 4 weeks of experiment.

After 2 weeks of experiment, blood samples were collected from the mice in group 1,2 and 3 by direct cardiac puncture, serum was separated from the blood by centrifugation of 3000 rpm for a 15 minutes , which is then transferred to be cooled at  $-20$  °C until biochemical analysis, the parameters and the respective methods are the following (Aspartate aminotransferase (AST), Alanine aminotransferase (ALT) and Alkaline phosphatase (ALP)(IU/dl),in blood serum using commercial kits and spectrophotometer according to [11] .

Serum concentration of urea was determined by enzymatic method (Urease- Modified Berthelot Enzymatic- Colorimetric), according to Randox Company kit [12]. However, measurement of serum creatinine was done by using colorimetric method for the determination of creatinine levels in serum, according to Randox Company Kit [13]. Also, the reproductive hormone testosterone was measured according to [14].

On the other hand, after the fourth week of experiment blood samples were collected from the mice in group 4, 5 and 6 to be chemically analyzed by the same way as group 1, 2 and 3.

At the end of every experiment (after 2 weeks and after 4 weeks), the mice were slaughtered by to take the specimens of (Liver, Kidney and testes) and each specimen was kept in a glass container containing 10% formalin saline for 24 hrs, the tissue were trimmed and the specimens were washed using tap water for 1-2 hrs and transferred to the same previous steps of histology [15].

The statistical analysis were performed by using one-way analysis of variance by completely randomized design (CRD) and differences obtained by statistical analysis were compared with means according to [16].

### Results and Discussion

Liver is the natural position for detoxification, it is considered one of the most important organs, it is affected by toxins that lead to disturbance of many functions such as; degeneration, swelling, inflammation and ending by necrosis (complete destruction of the cells) and these changes depend on the intensity of pesticide [5].

Results in Table-1 indicate that the effects of different concentrations of super cyren pesticide 5 and 10 ml/Kg on AST enzyme of mice after different periods (2 and 4 weeks), it's measured significantly  $5\pm0.13$  and  $6\pm0.17$  U/L in control groups respectively to  $8\pm0.13$ ,  $9\pm0.19$  respectively after 2 weeks and  $13\pm0.11$ ,  $16\pm1.7$  respectively after 4 weeks. Therefore, we found that after 2 weeks there are no differences between the two doses: 5 and 10 ml ( $8\pm0.13$  and  $9\pm0.19$  U/L) respectively. As well there was significant increase in AST after 4 weeks in 5 ml and 10 ml doses ( $13\pm0.11$  and  $16\pm1.7$  U/L) respectively.

**Table 1**-Effect of different concentration of supercyren pesticide (5 and 10 mg/Kg B.W.) on Liver function of mice after different periods (2 and 4 weeks).

Items	Control 1	Control 2	After 2 weeks		After 4 weeks	
			5mg	10 mg	5mg	10mg
Aspartate aminotransferase (AST) U/L	$5\pm0.13a$	$6\pm0.17a$	$8\pm0.13b$	$9\pm0.19b$	$13\pm0.11c$	$16\pm1.7d$
Alanine aminotransferase (ALT) U/L	$15\pm0.12a$	$16\pm0.18a$	$18\pm0.12a$	$28\pm1.22b$	$40\pm1.31c$	$55\pm3.11d$
Alkaline phosphatase (ALP) U/L	$360\pm5.15a$	$365\pm6.7a$	$380\pm8.7a$	$420\pm5.12a$	$520\pm3.3b$	$606\pm3.3c$

a,b,c,d represent the significant difference between groups with different concentration and different periods.

The present study showed that the effect of supercyren on ALT and ALP in treated mice in comparison with control groups similar to the results of AST level as shown as in Table-1. We observed toxic effect after 4 weeks of oral treatment on male mice. Supercyren caused significant increase in AST, ALT and ALP levels at high doses 10 mg/Kg after 4 weeks, compared with low dose of pesticide and control groups that led to liver injury and tissue damage that is related to ALT and AST elevation. These results agree with the previous study of [1] and [17].

These results go along with the histological lesions that were observed in the liver. Also, liver damage caused by supercyren pesticides obviously affects protein formation, these results agree with [17].

AST and ALT are considered one of the most important marker enzymes in the diagnosis of damaged hepatocytes because it is released from destructed cells to the blood. Hayder et al [18] during their study on white mice treated with super cyren pesticides they mentioned that there is increase in the levels of AST and ALT enzymes during the necrosis in hepatocytes which lead to increase the

permeability of cell membrane that leads to the release of these enzymes to blood. Increase in these enzymes indicates acute cell necrosis which is caused by toxins [17]. The increase in period of time exposure causes worse changes [19].

Table-2 shows significant increase in creatinine and urea concentration in blood serum of mice treated with oral administration of super cyren pesticide at dose 10 mg after 4 weeks compared with 2 weeks or control. Results of the present study are in agreement with previous reports of [17].

**Table 2-** Effect of different concentrations of supercyren pesticide (0.5 and 1 mg/Kg B.W.) on Kidney function of mice after 2 and 4 weeks.

Items	Control 1	Control 2	After 2 weeks		After 4 weeks	
			5mg	10 mg	5mg	10mg
Urea (mg/dl)	39±2.1a	41±3.2a	48±2.1b	52±3.4b	53±3.21b	67±3.2c
Creatinine (mg/dl)	0.6±0.02a	0.7±0.03a	0.8±0.02a	1.1±0.02b	1.15±0.02b	1.45±0.02c

a,b,c represent the significant difference between groups with different concentration and different periods Creatinine is a break-down product of creatinine phosphate in muscle, and is usually produced at a fairly constant rate by the body, it is chiefly filtered out of the blood by the kidneys (glomerular filtration and proximal tubular secretion), if there is a defect in kidney filtering, creatinine blood levels rise therefore, creatinine levels in blood and urine may be used to calculate clearance which reflects the glomerular filtration rate [20]. Serum creatinine may indicate changes in kidney function [21].

Results in Table-3 indicate that the effect of high dose of super cyren 10 mg after four week of oral administration has led to a significant decrease in testosterone hormone  $0.5\pm 0.01$  mg/ml compared with the other dose and control groups, that indicate the significant effect of pesticide on the production of testosterone from the testes.

**Table 3-** Effect of different concentrations of super cyren pesticide (0.5 and 1 mg/Kg B.W.) on Testosterone hormone levels of mice after 2 and 4 weeks.

Items	Control 1	Control 2	After 2 weeks		After 4 weeks	
			5mg	10 mg	5mg	10mg
Testosterone mg/ml	1.4±0.02a	1.3±0.02a	1.2±0.02b	1±0.01b	0.7±0.03c	0.5±0.01c

a,b,c represent the significant difference between groups with different concentration and different periods.

The liver is a vital organ in the body that is responsible for detoxification of toxic chemicals and drugs, thus it is the target organ to all toxic chemicals [19] and [22]. Histological examination of liver in mice treated with 5 and 10mg/kg of super cyren pesticide for 2 & 4 weeks Figure- (2,3,4 and 5) respectively further more Figure- 1 as a control, the result showed that the damage in the liver tissue increases with increasing the dose and periods compared with control liver histology.

That is Clear in Figure-5 when mice treated with 10mg/kg B.W for 4 weeks showing plurality space of necrosis, enormous number of inflammatory cells infiltration in the portal area, irregular dilation of sinusoid that only consist of a discontinuous layer of fenestrated endothelial cells a. Congestion of blood vessels refers to advanced liver tissue damage that could also affect liver function these outcomes had occurred after treatment with super cyren pesticide, especially when treated with high dose for long period (4 weeks). Liver contain Several enzymes that oxidize antibiotics forming metabolites, enzymes conjugate to these metabolites forming a more polar layer to facilitate excretion and prevent accumulation of harmful substances in the body. However biotransformation also may induce toxicity when metabolites are not conjugated to the enzymes, and so they bind to and damage cellular structure, overloaded biotransformation cause massive destruction of essential proteins or lipid membrane and cause cell death [22]. These results agree with the result of Majdy and Nowfel (2008) who studied the toxic effects for different concentration of organophosphorous chlorpyrphous pesticide on some histological and physiological features of mice by oral administration for 2 and 3 weeks, after 21 day of experiment

the GOT and GPT increased and the liver is natural position for detoxification which lead to disturbance of it is normal function in the form of degeneration, swelling and inflammation ending by necrosis and complete destruction of the cells and these changes depends on the intensity of the toxic effect of pesticide [5]. Most of organophosphurs pesticides compounds diffuse easily through the hepatocytes membranes and affect these membranes function by increasing it is permeability to water and leading to hepatocytes swelling, also, they reported that there is a loss in the hepatic cords division and hepatic cord and an increase in phagocytosis and granulocytic reaction which initiate the inflammation around the bile ducts. Sabah & Dalal [20] showed that when rabbits are exposed to high temperature (38 ° C) it affects the liver tissue by dilation of hepatic sinusoid, an interstitial hemorrhage, sever fatty change and mild inflammatory cells infiltration in the portal area, there is also a focal necrosis area, congestion and cell apoptosis Ayser [22] showed in the histological section of liver in rat treated with 50,100, 200 g/ kg of B.W. fenel consumption for 10, 20, 30 days focal area of necrosis, inflammatory cells infiltration and congestion of blood vessels in mice group with 200 g/kg of B.W. fenel consumptions for 10 days. But it seems to show worse effects on experimental group of 30 days fenel consumption, as section of liver show wide area of necrosis and inflammatory cells infiltration in addition to sinusoidal dilation with congestion of blood vessels compared with histological section of liver from control rats These changes in the liver tissue correspond to the results obtained in physiological changes in AST, ALP, and ALP enzymes.

Kidney section showed different histological changes after treatment with super cyren pesticide in concentration of 5 or 10 gm./kg B.W. for 2 and 4 weeks Figures- (7 8 9 and 10) compared with control Figure- 6. Showing many effects on kidney tissues. In section of kidney from mice group treated with 10mg /kg B.W. of super cyren pesticide for 4 weeks there is degeneration of kidney tubules, hyperplasia of kidney tubules and necrosis of renal tubules which was the larger effect on the kidney tissue this indicates that the greater the pesticide concentration and the exposure days, the more likely the tissue will be affected. These changes in kidney tissues correspond to the results obtained in physiological changes in urea and creatinine. These results agree with Majdy and Nowfel [17] who studied the effects of chlorpyrphous pesticide histologically on mice kidney tissue, they pointed to the tissue damage of kidney that lead to disruption of natural renal filtration. The observed degeneration of necrosis in epithelial cells that lined the renal tubules and glamour cause loss of ability of tubules to reabsorb and filter the large molecules such as proteins, minerals, salts and vitamins also disruption in urea filtration which lead to increase its levels in the blood also these results agree with [22] who showed that the study on the mice resulted in increasing urea, total protein and creatinine, this could be related to the high dose of fenel and long duration of exposure which caused degeneration and necrosis of kidney cells and damage peritubules that lead to prevention of secretion of urea so it's levels increased in blood also it lead to high levels of creatinine and total protein in serum because of the imbalance that occurred in the kidney function that balance between cell death and cell proliferation which control the organ size. many classes of toxic chemical are capable of inducing acute cells injury followed by death.

Testes section showed histological changes after treatment with 5 and 10 mg/Kg B.W. of super cyren pesticide for 2 and 4 weeks Figure-(12, 13, 14 and 15) compared with control Figure-11. We noticed more necrosis in seminiferous tubules and damage of straight tubule in the rate's testis, leading to the death of sperms inside seminiferous tubules in section of testis from mice groups treated with 10mg/kg of super cyren for 4 weeks. Also these changes go along with the physiological effects in testis (low concentration of testosterone hormone (0.5 mg/ml) in mice treated with 10mg/kg for 4 weeks. The hormonal inhibition and the decrease in sperm count and sperm motility are perhaps of low androgen levels [23].

Many pesticide agents are reported to cause variable changes in brain on repeated exposure, which have been related to hypoxia, hypoglycemia, or damage to cell ion homeostasis [24]. Organometry studies on the liver also suggested increase in the relative weight to the extent of 37.89% males after 30 days of insecticide treatment. The increased relative weight of liver was probably due to the functional hypertrophy of the smooth endoplasmic reticulum and increased drug metabolizing multienzyme complex as suggested by [25]. Lower dose (5mg/kg/day) of cypermethrin pesticide produced mild disorganization of hepatic laminae and higher dose (20mg/kg/day) produced necrosis of hepatic cells, with pyknotic nuclei and dilatation of sinusoids with highly disrupted hepatic laminae in

male rats, Fat degeneration and necrosis of hepatocytes have been observed after exposure of animals to several hepatotoxicants. [26].

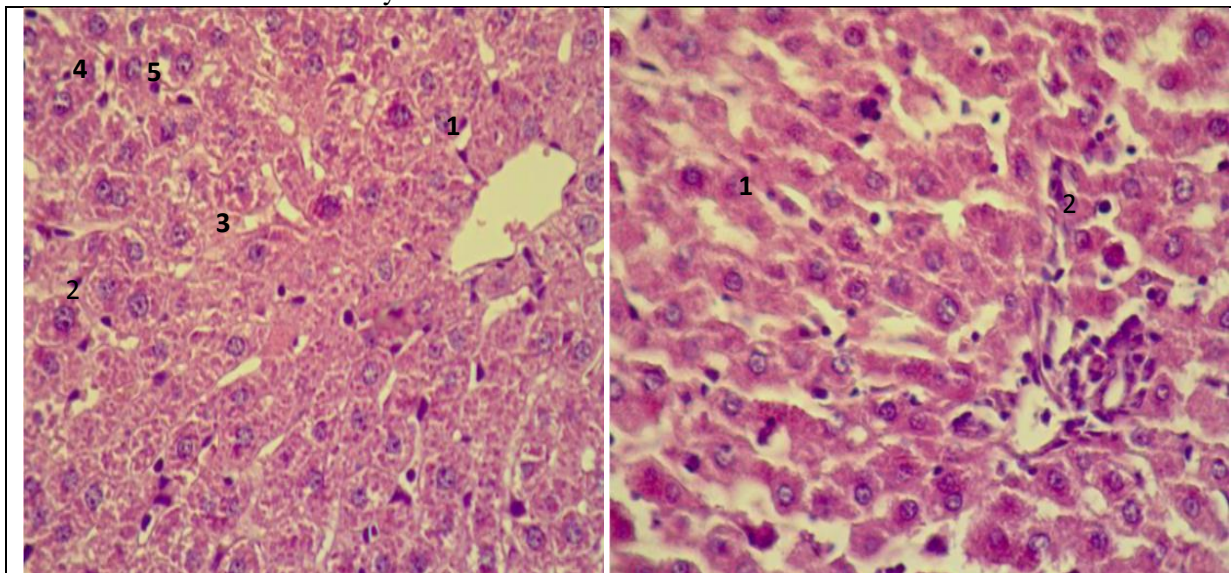
Cypermethrin at repeated oral doses of 5 and 20mg/kg/day produced no apparent morphological changes in kidney in male rats. However, relative weight of kidneys reduced to the extent of 27.27% in males. Cypermethrin produced alterations in the histoarchitecture of kidney, especially at higher doses. Lower dose produced sloughing of renal tubular epithelium, but no effect on glomeruli. Higher dose produce mild hemorrhage, sloughing of epithelial cells, shrinkage of glomeruli, and necrosis of renal tubules on 30<sup>th</sup> day of insecticide treatment, leakage of lysosomal enzymes may occur, thereby causing cell necrosis and renal damage (Grewal and Sandhu, 2010).

### Conclusions

1. Long term exposure (4 weeks) to supercyren pesticide with high doses (10mg) increased Liver enzymes (AST, ALT and ALP) serum levels, while low doses (5mg) and short term (2 weeks) exposure showed low significant effects.
2. Long term exposure to supercyren with high doses increased renal function enzymes (Urea and Creatinine) levels, while low doses and short term exposure showed low significant effects.
3. Long term exposure to supercyren pesticide with high doses decreased testes hormone (Testosterone) serum levels, while low doses and short term exposure low significant effects.

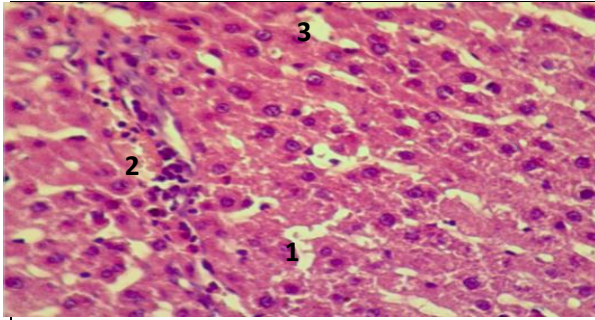
### Compliance with Ethical standards:

The authors declare that they have no conflict of interest

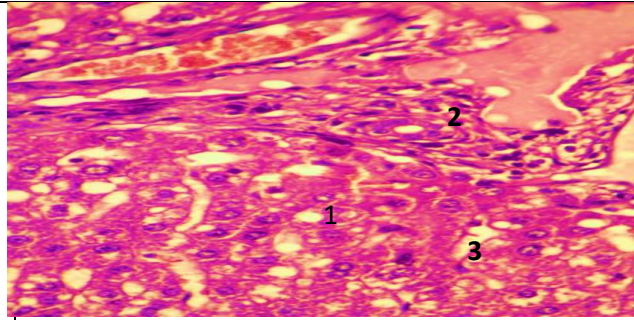


**Figure 1-** Section of liver from mice control group showing :- 1. presence of many cells around central veins 2. Making of hepatocytes as a ligament around central vein 3. Showing normal sinusoid 4. Outcrop of stellate macrophages 5. Outcrop of layer of fenestrated endothelial cells (400X) H&E

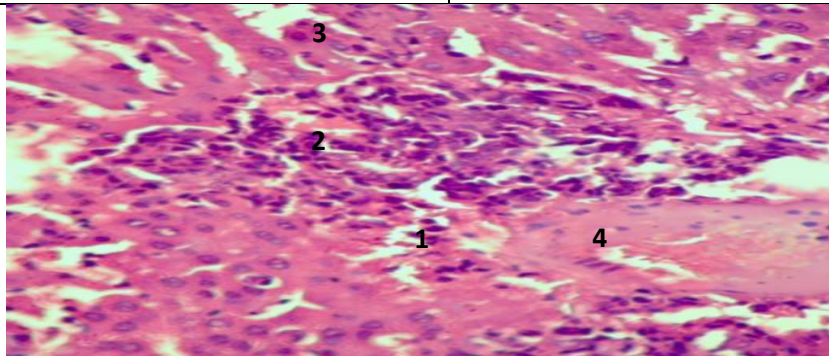
**Figure2-** Section of liver from mice groups treated with 5mg/kg B.W of supercyren pesticide for 2 weeks, showing 1. There is dilation of sinusoid 2. Some moderate changes in hepatocytes (400X) H&E.



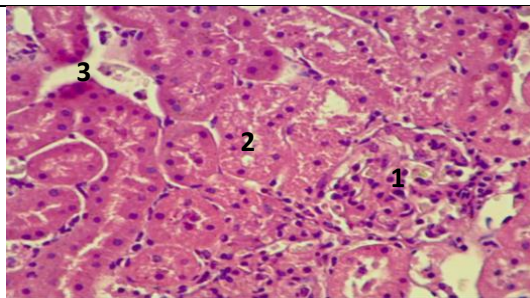
**Figure 3-** Section of liver from mice groups treated with 10 mg\kg B.W. of supercyren pesticide for 2 weeks , showing 1.A scattered necrosis area 2. There is a mild inflammatory cells infiltration in the portal area . 3. There is also dilation of sinusoid (400X) H&E.



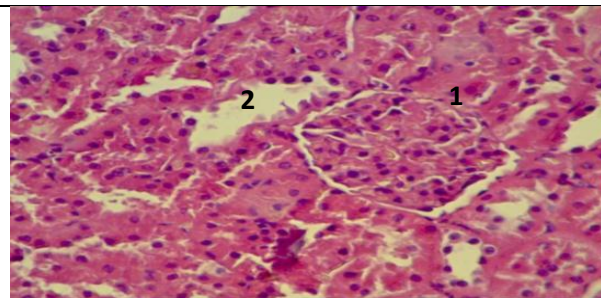
**Figure 4-** Section of liver from mice groups treated with 5mg\kg B.W. of supercyren pesticide for 4 weeks , showing 1. Acute fatty changes 2. Kind inflammatory cells infiltration in the portal area 3.Necrosis and congestion in the central area and some cell apoptosis (400X) H&E.



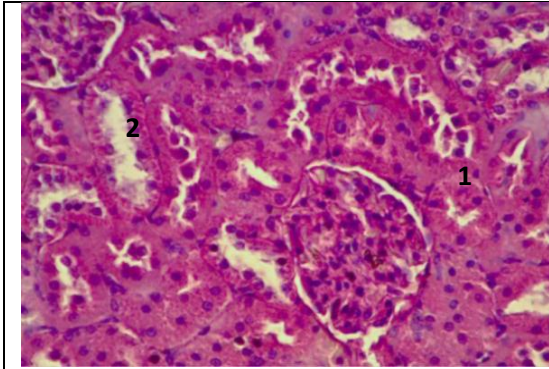
**Figure 5-** Section of liver from mice groups treated with 10 mg\kg B.W. of supercyren pesticide for 4 weeks, showing: 1.plurality space of necrosis 2. Enormous area of inflammatory cells infiltration in the portal area 3. Irregular dilation of sinusoid consist only of the a discontinuous layer of fenestrated endothelial cells 4. Overcrowding of the portal vein and an arteriole (400X) H&E.



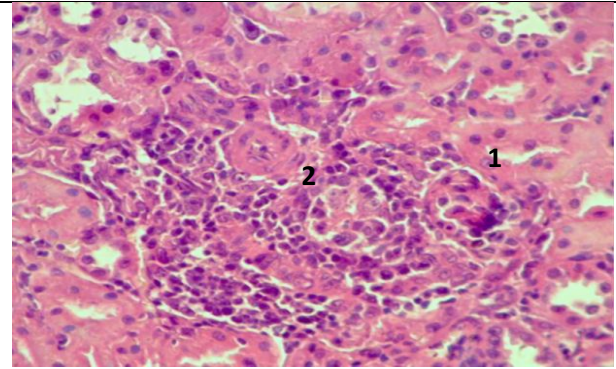
**Figure 6-** Section of Kidney from mice control group consist of: 1.The glomerular filtration barrier consist of three layered components: The fenestrated capillary endothelium, the glomerular basement membrane, and filtration slits between podocyte processes.2.Cuboidal epithelium of the proximal convoluted tubule .Thick ascending limb of the nephron loop is straight as it enters the cortex , and then becomes tortuous as the distal convoluted tubule (400X) H&E.



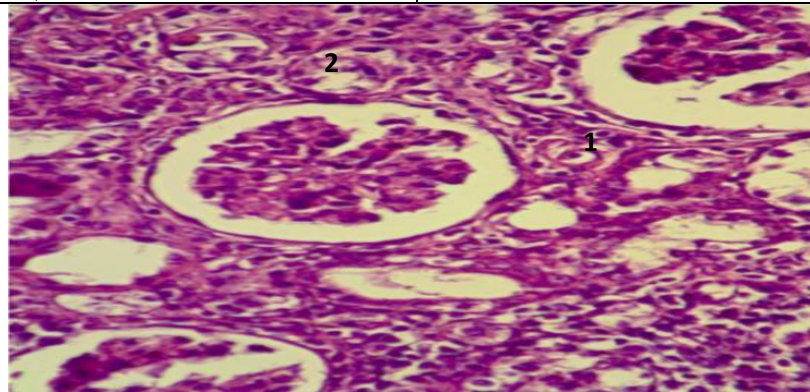
**Figure7 -** Section of kidney from mice groups treated with 5 mg\kg B.W. of supercyren pesticide for 2 weeks , showing disintegration from the effect of pesticide in the simple cuboidal cells of these tubular of the proximal convoluted tubules and cells of the distal convoluted tubule (400X) H&E.



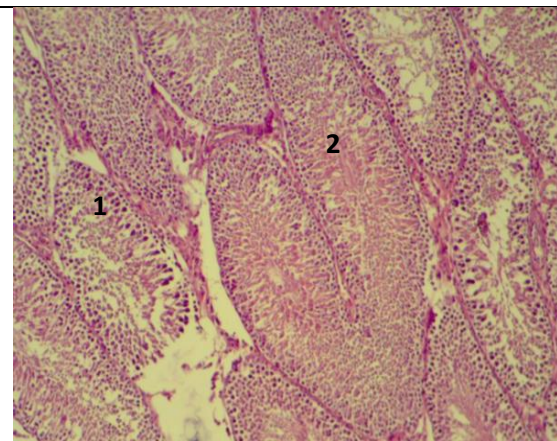
**Figure 8-** Section of kidney from mice groups treated with 10 mg/kg B.W. of supercyren pesticide for 2 weeks showing disintegration in the renal epithelium of 1. Simple cuboidal epithelium of the proximal convoluted tubules 2. Distal convoluted tubules (400X) H&E.



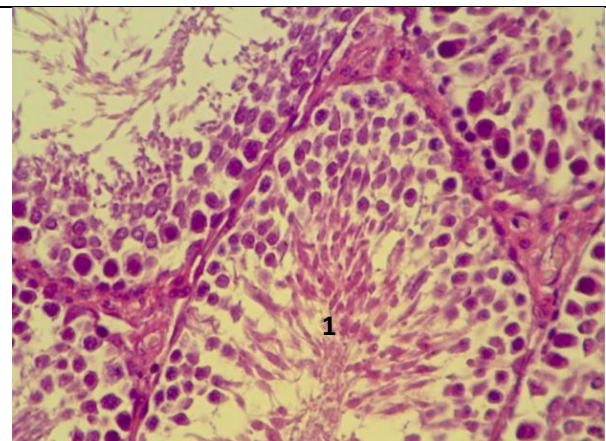
**Figure 9-** Section of kidney from mice groups treated with 10 mg/kg B.W. of supercyren pesticide for 4 weeks showing :1.Necrosis in the simple epithelium , cuboidal renal tubules2. Numerous inflammatory cells infiltration (400X) H&E.



**Figure 10-**section of kidney from mice groups treated with 10mg/Kg W.B. of super cyren pesticide for 4weeks showing 1. Degeneration of kidney tubules 2. Hyperplasia of kidney tubules &Necrosis of renal tubules (400X) H&E.

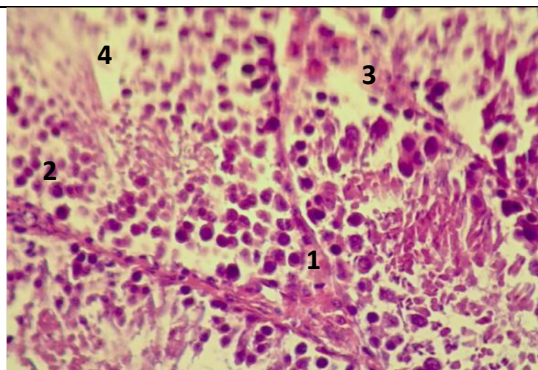


**Figure11-**section of normal structure of testis from mice (control groups)shows : 1. normal seminiferous tubules of , 1.normal tubule lumen and sustentacular cells and spermatogonia in the wall 2. in the middle presence of nature spermatids and inside lumen sperm cells (400x) H&E.

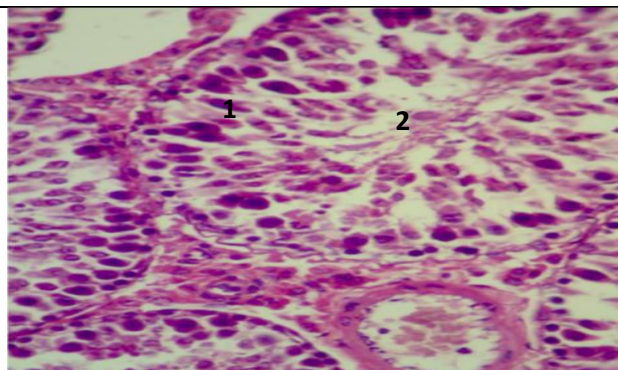


**Figure 12-** section of testis from mice groups treated with 5mg/Kg B.W. of supercyren pesticide for 2 weeks showing 1. Testicle has many seminiferous tubules in the lobules produced sperm (400x) H&E.

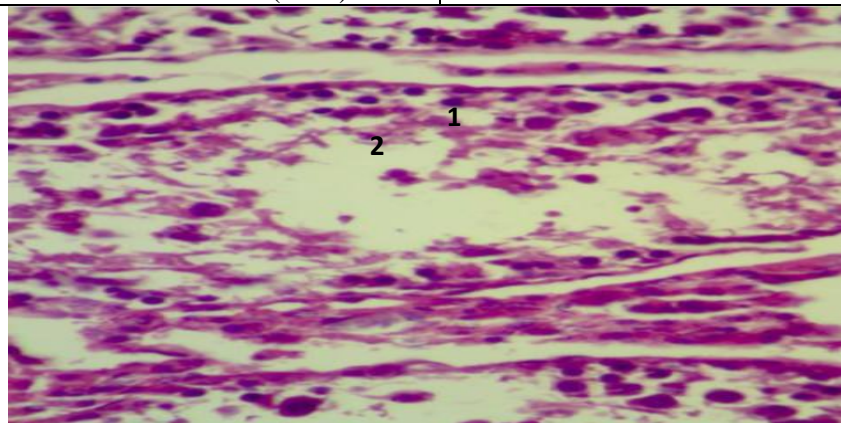




**Figure 13**-section of testis from mice groups treated with 10mg/kg B.W. of super cyren pesticide for 2weeks showing 1. Interstitial cells which secrete testosterone hormone 2. seminiferous tubules produce male reproductive cells 3. Some necrosis 4. Some spermatozoa inside the lumen (400x) H&E.



**Figure 14**-section of testis from mice groups treated with 5mg/kg B.W. of super cyren pesticide for 4 weeks showing 1. necrosis in stratified epithelium (seminiferous epithelium) 2. Depration in development of spermatogenesis (400X) H&E.



**Figure 15**- Section of testis from mice groups treated with 10mg/kg B.W. of super cyren pesticide for 4 weeks showing : `1. More necrosis in seminiferous tubules and damage of straight tubule to the rete testis 2. Caused death of sperm inside the lumen of seminiferous tubules (400x) H&E.

## References

1. Alfartosi, A.H. **2003**. Determiration of chlorpyrifose residues in data palm trees and its soil by gas chromatography technique and studying of some physiochemical characteristics. Thesis, Cole. Agric. Univ. Basrah. pp74.
2. Ufodike, E.B.C., Omoregic, E. **1994**. Acute toxicity of water extract of barks of balanites aegyptica and Kigelia africana to Oreochromis niloticus. *Aqua. Fish. Mgt.*, **62A**: 873-879.
3. Krueger, H.R. and Obrien, R.D. **1989**. Relationship between metabolism and differential toxicity of malathion and chlorpyrifose in insect and mice. *J. Econ. Ent.*, **52**: 1063-1067.
4. Ramesh, N., Balakrishna, M.P. and Philip, K. A. **1996**. In vivo and vitro effects of an organophosphate pesticide, monocrotophos on acetylcholinestrerase activity in wistar rate. *J. Environ. Biol.*, **17**: 235-238.
5. Luty, S. Tokarska, M. and Latuszynska, J. **2002**. Dermal absorption and distribution of C14DDT in the organs of rat. *Ann. Agric. Enverson. Med.*, **9**: 215-223.
6. Vander, A., Sherman, J. and Luciano, D. **2001**. *Human physiology: The mechanism of body function*. 8<sup>th</sup> ed. McGraw- Hill companies. Inc. (USA).
7. Rowen K. and Zetterman, MD. **2009**. Evaluation the patient with Abnormal LiverTests. *Medscape Gastroenterology*.

8. Nada, A.S., Ahmed, O.M., Abdel-Recheim, E.S., Amin, N.E. and Ali, M.M. **2011**. Foeniculum vulgare Mill. Essential Oil Attenuates some Biochemical Disorders Induced by Y-irradiation in Male Rats. *J. of Radiation Research and Applied Sci.*, **4**(1): 199-217.
9. Shier, D., Butter, J. and Lewis, R. **2009**. *Hole's essential of human anatomy and physiology*. 10<sup>th</sup> ed., McGraw Hill Company, New York (USA).
10. Mohammed, M. Zekry Yahya. **1990**. Pesticide types and their uses. The Ministry of Agriculture and Irrigation, Iraq.
11. Reitman, S. and Frankel, S. **1957**. Calorimatree methods for determination of serum alanine and aspart aminotransferase. *Amer. J. Cli. Path.* **28**: 56pp.
12. Fawcett, J. K. and Scott, J. E. **1960**. A Rapid and Precise Method for the Determination of Urea. *J. of Clin. Path.* **13**: 156-159.
13. Bartels, H. and Bohmer, M. **1972**. Serum creatinine determination without protein precipitation. *Clinica Chimica Acta* . **37**: 193-197.
14. Dorfman, R. I. and Shipley, RA, ED. **1956**. *Androgens, Biochemistry, Physiology and Clinical Significance*. New York, John Willey and sons.
15. Bancroft, J.D. and Stevens A. **1982**. *Theory and practice of histological techniques*. 2<sup>nd</sup> ed. Churchill livingstone. Edinburgh.
16. Snedecor, G.W. and Cochram, W.G. **1980**. *Statistical methods*. 10<sup>th</sup> ed. Iowa state Univ. press, Ames. (USA).
17. Majdy, F., Majeed, Al-Ali and Nowfel, H., Jassim **2008**. Study of some physiological and histological changes in Mus Musculus mice after exposure to chlorpyrphos pesticide. *Bas. J. vet., Res.*, **7**(2).
18. Hayder, M.A., Hasan, M. and Mohieldein, A.H. **2013**. Comparative Levels of ALT, AST, ALP and GGT in liver associated diseases. *European J. of Experimental Biology*, **3**(2): 280-284.
19. Rebeh, N.M. and Aboraya, A.O. **2014**. Hepatoprotective effect of Dill (Anethium graveolens) and fenel (Foeniculum vulgare) oil on hepatotoxic rats. *Pakistan J. of Nutrition*, **13**(6): 303-309.
20. Sabah, A.H. Abd Al-Rahman and Dalal Abd Al-Sattar. **2016**. Effect of the thermal changes on physiological, biochemical and histological trait pregnant and embryo of NZW Rabbits. *International J. of Advanced biological Research*, **6**(2): 2250.
21. Soliman, A.Z.M., El-Kady, R.I., El-Shahat, A.A., Sedki M.Z. **2000**. Effect of some commercial growth promoters on the growth performance and caecum microbiology of growing NZW rabbits. *Egypt. J. Rabbit Sc.*, **10**: 239-252.
22. Ayser, Abdullah Shafiq. **2017**. A study of Hormonal, biochemical and histological effects of fennel seeds (Foeniculum vulgare) on thyroid gland, liver, kidney and testes in male rats. Thesis Al-Mustansiriyah Univ. College of Science, Biol. Dep.
23. Ibrahim, A.A.E. **2008**. Correlation between fennel er anise-oil administration and damage to the testis of adult rats. *Egyptian J.Bio.***10**: 62.
24. Anthony, D.C., Montine, TJ, Graham, DG. **1996**. *Toxic response of the nervous system. The Basic Sci., of poisons*. Vol.5 New York; McGraw-Hill, pp: 463-486.
25. Ayub-Shah, M.A., Gupta,PK, Tandon M.K. **1996**. Effect of permethrin; A sythetic pyrethroid on pentobarbitone induced sleeping time and hepatic microsomal constituents in mice. *Ind J. Toxicol.*, **3**: 19-23.
26. Grewal, K.K. and Sandhu, H.S. **2010**. Toxic impacts of cypermethrin on behavior and histology of certain tissues of Albino rats. *Toxicol Int. Jul.Des.*, **17**(2): 94-98.