



Histological study of the Isotretinoin drug effect on the intrauterine prenatal development in the pregnant mice

Lina A. Salih

Department of Biology, College of Science. University of Baghdad, Baghdad, Iraq.

Abstract

The isotretinoin drug is 13-cis-retinoic acid, is the treatment of severe acne and some skin cancers and used for dermatological conditions, this study was designed to detect the toxic role of the isotretinoin on the intrauterine development after implantation in albino mice during pregnancy. There are very little studies which indicating the side-effect of this drug on intra-uterine growth, so in the present research we tried to study the toxic effect of isotretinoin on the endometrial changes of uterus during the 2nd. and 3rd. trimester of gestation in pregnant mice after treatment with single chronic dose of the Isotretinoin drug (20 mg/B.wt) from first day of gestation until 21 days the last day of gestation.

The present study examination of the uterus during the particular gestational days were perceived some fault in the endometrium tissue of the uterus since the hyperplasia of the lining epithelium of the uterus and thickening of the endometrium because of propagation of the endometrial glands and stroma and widening of the endometrial cavity in both control and treated groups of pregnant mice after the 7 day of gestation, we found some morphological changes appear in the pregnant mothers like, more thickness skin and change color of the body fur from white to yellow-whitish color, and less physical active and drop in appetite.

The morphological changes in the pregnant mice after treated with (20mg / kg B.wt), isotretinoin dose, appear a significant decrease ($p \leq 0.05$) in the body weight. The histological results show a decreased in the numbers of the papillary projects of the endometrial tissue and change with few in numbers of the endometrial glands and loss stroma with thickness of the lining epithelium and this may because the resorption of the embryos inside the uterus compared to the control group.

The present study clearly determine that the effect of isotretinoin on the histopathology of the uterus through pregnancy cause toxic on the embryos and result in resorption and damage the implanted embryos at altered particular gestational days in mice, as a result isotretinoin should be taking with attention and avoided at first post-implantation phase of gestation.

Keywords: :Isotretinoin, Intrauterine Development, Mice Lina.

دراسة نسيجية لتأثير عقار ايزوتريتاينون في التطور الجنيني داخل رحم الاناث الحوامل للفئران البيض

لينا عبد المطلب صالح

قسم علوم الحياة، كلية العلوم ، جامعة بغداد، بغداد، العراق.

الخلاصة

يعد عقار ايزوتريتاينون (13-cis-retinoic acid) علاج لحب الشباب المفرط وبعض سرطان الجلد وحالات الاصابات الجلدية. وضعت هذه الدراسة لتحديد الدور السمي لل ايزوتريتاينون في تطور النمو داخل

الرحم بعد عملية الانغراز في الفتران البيض خلال الحمل. يوجد عدد قليل من الدراسات التي استطلت على وجود تأثير جانبي لهذا العقار في الحياة داخل الرحم. لذا ففي هذا البحث حاولنا دراسة التأثير السام لل ايزوتريتاينون في التغييرات في البطانة الداخليه للرحم خلال الربع الثاني والثالث من الحمل في الفتران الحوامل بعد معاملتها بجرعة مفردة مزمنة من عقار ايزوتريتاينون (20 ملغم/ ون الجسم) منذ اليوم الاول من الحمل ولغايه اليوم 21 وهو اليوم الاخير من الحمل.

توصلت الدراسة الحالية الى وجود بعض النمو المفرط لنسيج البطانة الثلاثية للرحم خلال ايام الحمل المحددة وذلك بسبب توسع غددالبطانه الداخليه ونسيجها وتمدد تجويف البطانه الداخليه في كل من مجموعته السيطرة والمجاميع المعاملة للفتران الحوامل بعد 7 ايام من الحمل. وجد ظهور بعض التغييرات المظهرية على الامهات الحوامل مثل نتخن الجلد وتغير لون فرو الجسم من الابيض الى الالبيض المصفر، قله في الحركات الفيزيائية وانخفاض الشهية. اظهرت التغييرات المظهرية للفتران الحوامل بعد المعاملة ب جرعة 20 ملغم / وزن الجسم من ايزوتريتاينون انخفاض معنوي في وزن الجسم ($p \leq 0.05$) بينما وجدت النتائج النسيجية انخفاض في عدد البروزات الحليمية لنسيج البطانه الداخليه مع اعداد قليلة من غدد البطانه الداخليه وفقدان نسيجها يرافقه نتخن البطانه الثلاثية وهذا قد يعود الى اعاده امتصاص داخل الرحم مقارنة مع مجموعته السيطرة. بينت هذه الدراسة بشكل واضح تأثير ال ايزوتريتاينون في التشريح المرضي للرحم خلال الحمل الذي يؤدي الى سمية الجنين وبالتالي يؤدي الى اعاده امتصاص الاجنة المنغرزة وتضررها عند ايام مختلفة من الحمل في الفتران. وبالنتيجة فان عقار ايزوتريتاينون يجب ان يعطى بحذر ويفضل تجنبه خلال المرحلة الاولى من الحمل.

Introduction

Isotretinoin, vitamin A derived is a drug mutual use for cure of cystic acne used in many dermatological therapies as severe acne, ichthyosis, and some systemically cases, prevention of various types of skin cancers and leukemia. Isotretinoin is used 95% of the interval in young persons among 13 and 45 years of age. Retinoic acid also plays a part in form establishment and organ development through embryo ontogenesis [1]. Subsequently 1983, once the teratogenicity of Isotretinoin was main known in humans, the Food and Drugs Administration (FDA) [2] has seen regularity to make references to stability the necessities of patients with severe cystic acne to take Isotretinoin with the requirement to keep fetus from contact to this drug during pregnancy. However, Isotretinoin is at present the greatest mostly approved teratogenic medication in the USA and Canada [3]. In spite of its extensive treatment, there are increasing worries about its side effects especially its teratogenicity, and cause vital side effect nevertheless is quiet being active tropically and systemically in dermatological treatments [4]. Isotretinoin on the retinoic receptors of the nerve cells by modifying the normal changing growth factor beta (TGF- β) status [5], the texts are almost totally missing information about absolute effect of Isotretinoin on the morphology and histology of the pregnant women and their fetuses.[6] these malformations were attributed to the result of the Isotretinoin known to affect the neurogenesis of the developing brain causing reduction in the number of neurons in the frontal cortex of the growing brain when treated prenatally [7].

Materials and Methods

Mating of mice

Twenty female mice (n=20) were allowed to mate with one fertile sexually active male mice, weight between 20-30 g, 6-8 weeks old, provided with water *ad libitum* under 22°C and relation humidity of about 50%. The animals were casually particular for two groups (n=20, n=10), treated and control group separately. The animals were adapted for two weeks in the animal holdings. Vaginal smears investigations were first taken on every day earlier to mating, to identify the existence of spermatozoa in the smear to be the first, of pregnancy. The pregnant mice were divided into control group (n=10) and the treatment group (n=10), they housed individually in separated cages until 7 day of gestation.

Drug administration and animal groups

Isotretinoin was administrating orally using metallic oro-pharyngeal cannula after dissolved in vegetal oil, the Isotretinoin was administrated to pregnant mice after implantation from 7 dpc until 16

dpc one dose daily (20 mg/B.wt) the control group conventional equal volume of vegetable oil at the same selected days of gestation.

Results

Maternal and fetus observation

Before and after of gestation the morphological of the pregnant females was; a drop and change in the color of the fur to whitish-yellow and thickness in the treated group compared to the control group as shown in Figure- 1. also we noticed less active, decrease in the appetite, drop in the vision, these observations were concomitant with a significant decrease ($P \leq 0.01$) in weight (Table- 1) and in the number of the implanted fetus of the pregnant mice after the 7 dpc, in the treated pregnant animals compared to control group along the gestational days were selected (Tabl- 2) the present observation was compared to control group.

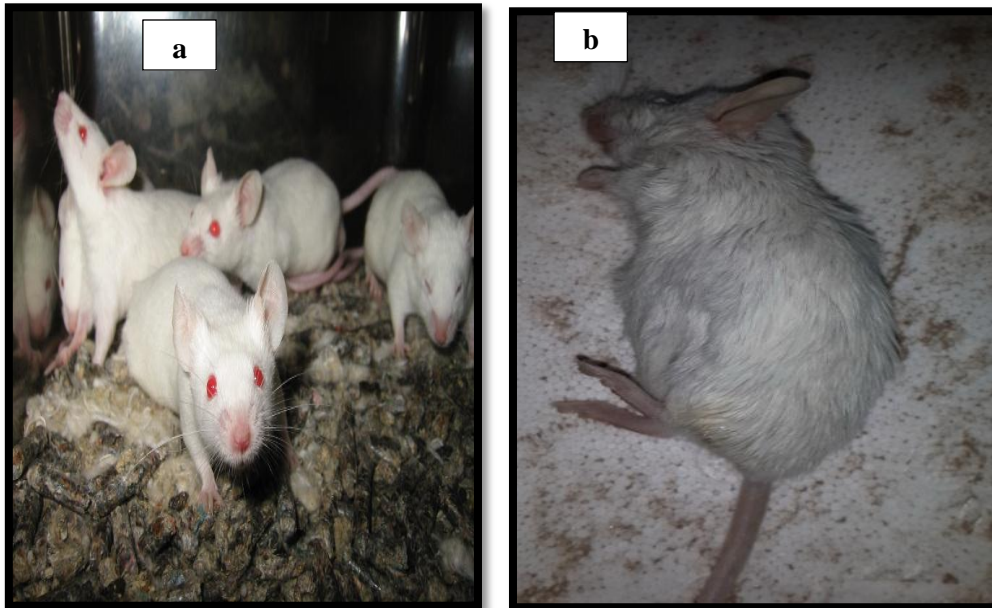


Figure 1- (a) control (b,c) , treated group with (20 mg/B.wt) Isotretinoin.

Table 1- Maternal mean average weight in control and treated group.

Gestational days (dpc)	Body weight (g)	
	Control group	Treated group
7	20.00 a	20.01 a
13	21.00 a	19.02 b
15	21.00 a	18.00 b
16	21.03 a	16.01 b

Significant at ($P \leq 0.01$) Means \pm SE

Different litter refer to significant difference at $p \leq 0.05$

Table 2- number of the implanted embryos in control and treated groups.

Gestational days (dpc)	Fetal number	
	Control group	Treated group
7	9a	1a
13	7a	1b
15	8a	3b
16	8a	0b

Significant at ($P \leq 0.01$) Means \pm SE

Different litter refer to significant difference at $p \leq 0.05$

Uterus observation

There were obvious morphological differences in the uterine horn of the pregnant mice in the treated groups at 7 until 16 dpc, low blood supply, weak horns group, compared with the control also could observe some implanted embryos at 15 dpc as shown in Figure- 2.

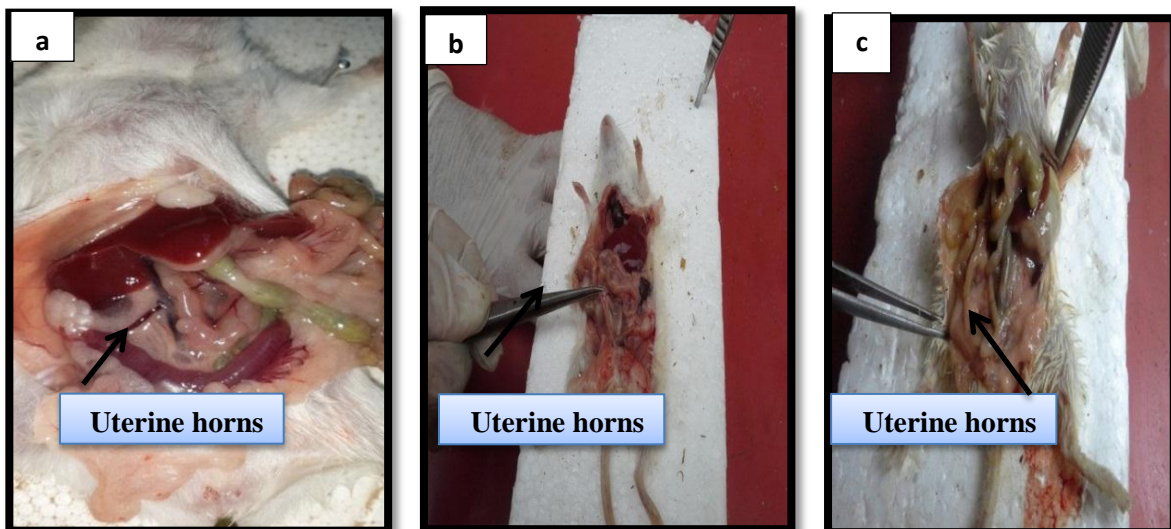


Figure 2- Uterine horn of the pregnant mice in control (a), treated group at 7 dpc (b) and treated group at 15 dpc.

Histological observations

Histological examination of the uterus of the pregnant mice treated in Isotretinoin was prepared at 7, 13, 15, 16 gestational days in control , treated animals. The results indicated endometrial glands and stroma and widening of the endometrial cavity in both control and treated groups hyperplasia of the lining epithelium of the uterus and thickening of the endometrium due to proliferation of the as shown in Figure- 3.

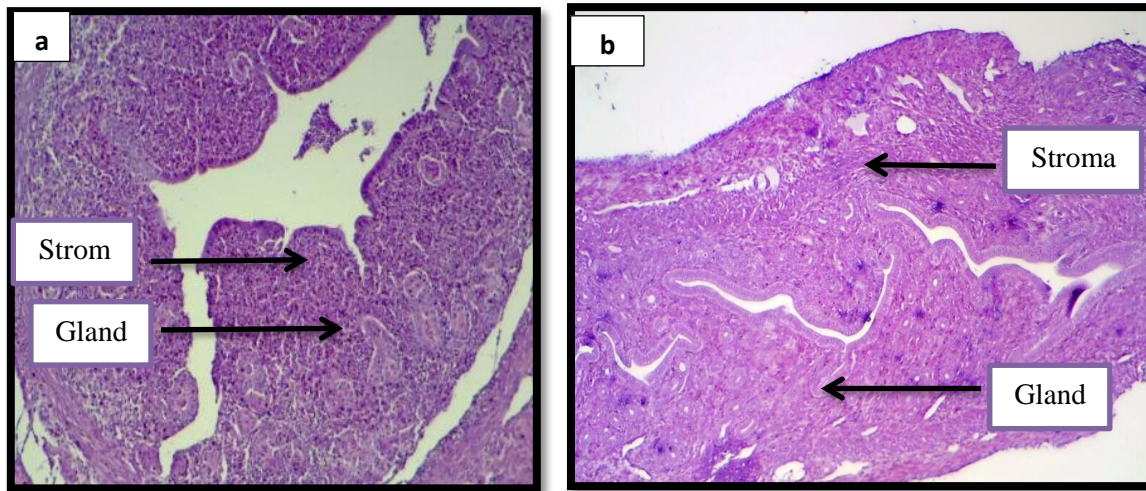


Figure 3- Sections in uterus of control group (a) and treated group with (20 mg/B.wt) Isotretinoin treated mice (b) in (7 day) of gestation (20x. H&E).

the tissue of the uterus of the pregnant mice of control and treated group at 13 day of gestation, the results were noticed a decreased of the papillary projects of the endometrial tissue and change with few in numbers of the endometrial glands and loss stroma with thickness of the lining epithelium compared to the control group, Figure- 3.

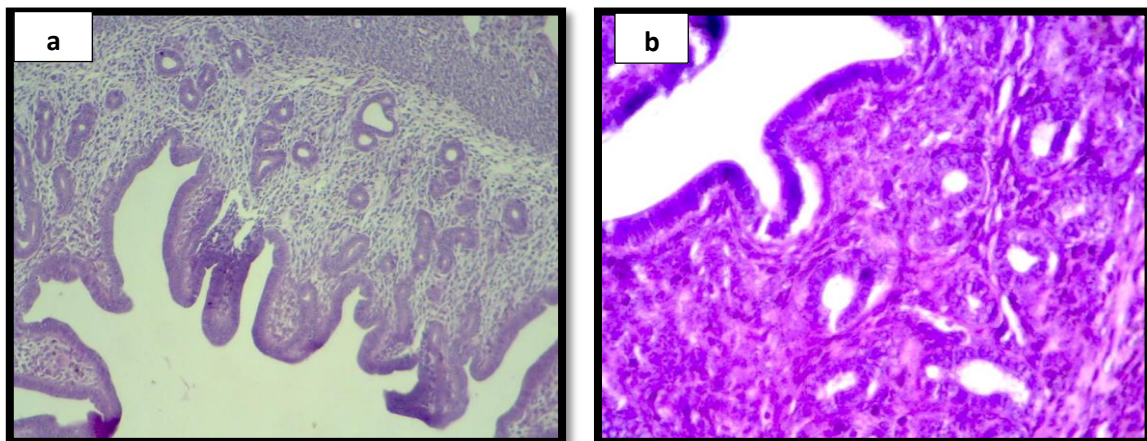


Figure 4-Sections in uterus of control group (a) and treated group with (20 mg/B.wt) Isotretinoin treated mice (b) in (13 day) of gestation (20x H&E).

The observation of the histological sections of the pregnant mice uterus treated with Isotretinoin drug at 15 day of gestation shown that thin cavity of the uterus with sloughing and necrotic material of implanted embryos with very loose texture of the stroma with few endometrial glands, also was noticed degenerative in the lining epithelium and necrotic tissue of placenta with decidual cells compared to the control group, as shown in Figure- 4.

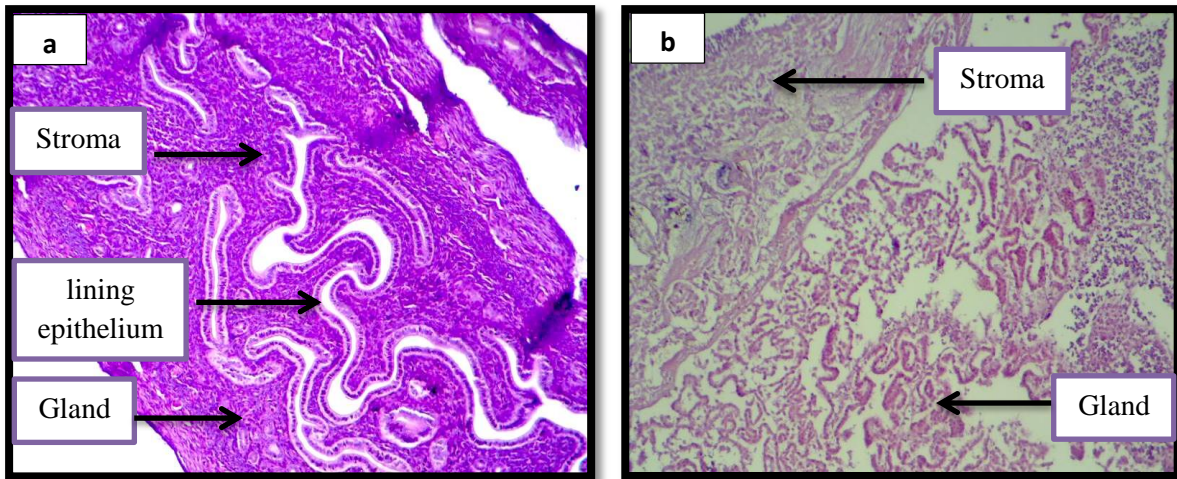


Figure 4- Sections in uterus of control group (a) and treated group with (20 mg/B.wt) Isotretinoin treated mice (b) in (15 day) of gestation (20x. H&E).

The histological sections of the uterus of the control and treated pregnant mice at 16 day of gestation, the existing study showed that no embryo materials could found, low lining epithelium, weak proliferation in the endometrial glands and canals compared to the control group, Figure- 5.

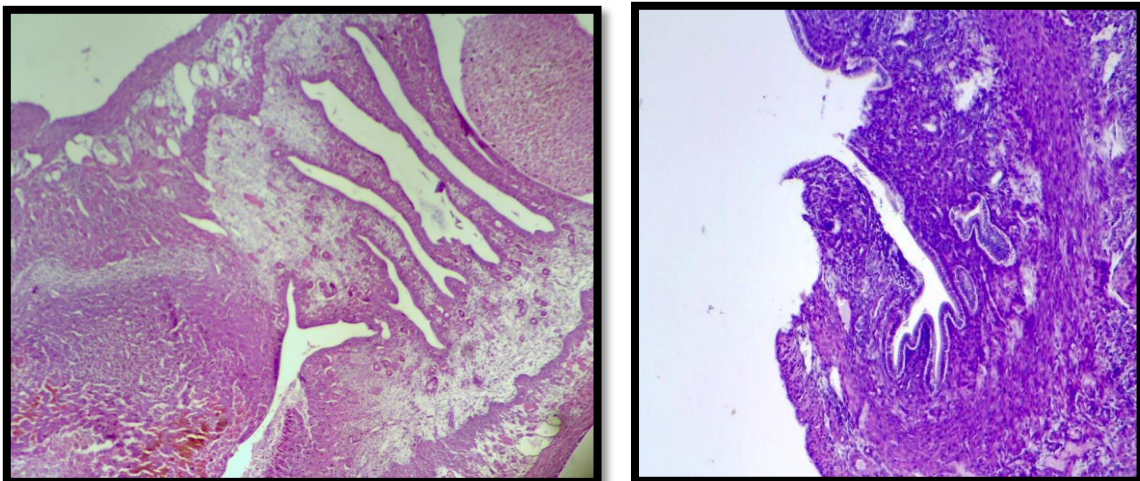


Figure 5-Sections in uterus of control group (a) and treated group with (20 mg/B.wt) Isotretinoin treated mice (b) in (16 day) of gestation (20x. H&E).

Discussion

Isotretinoin is a appreciated compound in the treatment of cystic acne and frequent additional dermatological disorders [8], later isotretinoin is an vital morphogen bringing design formation, it is practical to complete that excess isotretinoin may disorder the development and lead serious delay. In the current study, the results were dedicated some morphological alterations between the control and treated pregnant mice especially in the body weight and the color of fur of the body, these findings were agree with previous suggestions that since Isotretinoin is a artificial retinoid that prevents the differentiation of sebaceous glands, fixes the keratinization deficiency in the follicles and in some cases the skin loss its color. Inappropriately, retinoids are extremely teratogenic in humans, equal in the therapeutic dosage Even though the mechanism of action of Isotretinoin leading to the droplet in fur of the treated group is static unclear but it is identified that like other retinoids, isotretinoin works by DNA transcription shifting. [9], this effect declines the dimension and production of sebaceous off into the sebaceous glands, creates the cells that are sloughed off into the sebaceous glands fewer sticky, and hence less capable to form comedones. A loss in the weight of the maternal after gestation related to the weight before gestation and control group could be an indicator of drop in the appetite and ill health which essential have been produced by the release of free radicals [10], also related

systemic toxicity to release of free radicals and later a loss in weight and many other researchers investigated that this drug has low toxicity in pregnant mice, but the continuous use might cause defect in organs. Additional quantities of Isotretinoin are also teratogenic in animals, numerous animal studies have confirmed a possible adverse effect of this drug when managed during median and late pregnancy in mice, these findings were agree with our results, The mechanism of action of isotretinoin on the placenta has not been absolutely exposed, but may be associated with the decrease in the fibers of the connective tissues in the villus core of the placenta membrane [11]. These fibers which are likely to deliver the placenta with the pulsatile movement of the exchanged metabolites and gaseous products between maternal and fetal blood stream must have been inhibited by the systemic presence of isotretinoin The existing results shown the fall in the size and growth of the uterus

In the treatment group related to the control group and may occur reabsorption of the embryos during early gestational periods, many previous studies improved that the isotretinoin has a wide range of toxic effect on various systems [12] and in some observations. The work of Kocchar, 1967 which confirms the capacity of the isotretinoin to cross the placenta [13].

Previous studies the Isotretinoin on 59 pregnant females throughout the first 28 days of gestation, 20% had unprompted abortion and 43% of newborn had congenital malformation. Conversely the effect of Isotretinoin pre-implantation and early post-implantation embryo development stay unclear [14].

The histological examination of the uterus of the pregnant mice under the light microscopic level was achieved to estimate the histological variations in the endometrial tissue of the uterus during first and second trimester of the pregnancy after a single chronic dosage of the isotretinoin[15]. in the present study all the implanted embryos in the treated mothers at the selected gestational days were reabsorbed in the uterus this was conducted through the histological examination of the uterus, these findings agree with previous studies that improved the higher rate of post-implantation embryo resorption in retinoic acid treated mice than in control (35% vs 0%) [16] The isotretinoin treatment must be avoided any stage of gestation.

In conclusion, severe acne, skin cancer and infections mutual with pregnancy should be treated with caution,, if isotretinoin is to be active at all; most mainly during the first and second trimester of pregnancy.

References

1. Gudas, L.J. **1992**. Retinoids and vertebrate development. *J Biol Chem*, **269**: 15399-402
2. STASHOWER ME. 2003. Pregnancy rates associated with isotretinoin (Accutane) and the FDA. *J Am Acad Dermatol*, **49**: 1202-1203
3. Moskop, J C., Smith, M L., Devillek. **1997**. Ethical aspects of teratogenic medications: the case of isotretinoin. *J Clin Ethics*, **8**: 264-278
4. Amichai, B., Shemer, A., Grunwald, M. **2006**. Low-dose isotretinoin in the treatment of acne vulgaris. *J. Am. Acad. Dermatol*, **54** (4): 644–6.
5. Divya Premchandran, Sampath Madhyastha , Jai Aditya, **2013**.Teresa Joy, Sudhanshu Sekhar . Effect of Prenatal Isotretinoin Exposure on Neuronal Population of Prefrontal Cortex in Rats. *Research Journal of Pharmaceutical, Biological and Chemical Sciences*, **4**: 902-11.
6. Jennie, L., Close, Burak Gumuscu and Thomas, A. **2005**. Retinal neurons regulate proliferation of postnatal progenitors and Muller glia in the rat retina via TGFβ signaling. *Development*,**132**: 3015-26
7. Ofusori, D.A., Abdelkun, A.E., Jimoh, S.A., Komolafe, A.O., Falana, B.A., and Abayomi, T.A. **2007**. Teratogenic effect of isotretinoin on the morphology and palate development in rat fetuses. *African Journal of Biotechnology*,**6**: 120-8
8. Duell, E.A., Kang, S. and Voorhees, J.J. **1996**. Retinoic acid isomers applied to human skin in vivo each induce a 4-hydroxylase that inactivates only trans retinoic acid. *J. Invest. Dermatol.* , **106**: 316–320.
9. Divya Premchandran, Sampath Madhyastha, Jai Aditya, Teresa Joy, Sudhanshu Sekhar. **2014**. Effect of prenatal isotretinoin on postnatal development of rat retina and expression of double ecortin positive cells: Amorphometric and histopathological analysis. *Int.J.Pharm.and Phar.Sci.*, **6** : 623-626

10. Bremner, JD. **2003**. Does isotretinoin cause depression and suicide? *Psychopharmacol Bull*,**37** (1): 64-78
11. Akpantah, AO., Olabiyi, OA., Oremosu, AA., Noronha, CC. and Okanlawon, AO. **2006**. Assessment of the antioxidant potential of alcoholic extract of *Garcinia kola* seed in alcohol induced testicular oxidative stress in Spague-Dawley rat. *Nig. J. Health BioMed Sci.* ,**5**(1): 37-42
12. Halliwell, B, Gutteridge M. **1999**. *Reproduction and oxidative stress. Free radicals in Biology and Medicine* 2nd ed. Oxford Uni. Press. New York
13. Kocchar, DM. **1967**. Teratogenic activity of retinoic acid. *Acta. Pathol. Microb. Scand*, **70**: 398 - 404.
14. Sadler, TWE. **1995**. *Langman's medical embryology*. 7th ed. Williams & Wilkins, pp: 333-340.
15. Huang, Fu-Jen. **2008**. Effects of Retinoic Acid on Morula-stage Embryo Development in Mice. *Chang Gung Med J* , **31**: 44-51.
16. Vierira, A.S. and Melchiors, A.C. **2012**. The effect of isotretinoin on triglycerides and liver aminotransferases. *An Bras Dermatol.*, **87**(3): 382-7.