



ISSN: 0067-2904

Physiological and Immunological Study for the Effects of *Onopordum acanthium* L. Seeds Oil in Male Rats Treated with CCL₄

Husni Abdulla Mhammad*, Malika Kassim Najeeb, Amad M. Saleh Jubrail
Department of Biology, College of Science, University of Duhok, Duhok,

Received: 30/7/2021

Accepted: 18/9/2021

Published: 30/5/2022

Abstract

In this study, the attention was focused on the protective role of seeds oil from local *Onopordum acanthium* L. (cotton thistle) against tissues damage in the liver, kidney and spleen in male albino rats. Forty adult male rats were randomly divided into four equal groups including control group, rats were treated orally with seeds oil (0.5ml/kg), carbon tetrachloride (CCL₄) injected group, and last group was intoxicated with CCL₄ and daily treated with seed oil (0.5ml/kg). After four weeks of the experiment, rats were anaesthetized and blood was taken directly by cardiac puncture for the evaluation of studied parameters. Samples of liver, kidneys and spleen were fixed in 10% formalin for histological studies.

From the obtained results, no significant changes were seen in the estimated parameters in the group treated with oil only. In the group injected with CCL₄ and treated with oil extract, the level of serum lipids, liver enzymes, total serum bilirubin (TSB), tumor necrosis factor-alpha (TNF-α), C-reactive protein (CRP) and white blood cells (WBCs) were significantly reduced in comparison with untreated CCL₄ intoxicated group. The toxicity of CCL₄ on the level of fasting blood sugar (FBS), angiotensin-converting enzyme (ACE), high-density lipoprotein (HDL), renal function parameters, hemoglobin and body weight were ameliorated with seeds oil. These effective roles were further supported by the histopathological improvement of the liver, kidney and spleen tissues of rats against CCL₄. Conclusion: from the results of this study, it can be concluded that the extracted oil from local Iraqi *Onopordum acanthium* L. seeds reduced the tissue damages with an improvement of biochemical, hematological and immunological parameters during the four weeks of the experiment.

Keywords: Cotton thistle, Rats, Seed oil, CCL₄, Tissues damage, TNF-α, ACE, Histopathological improvement.

شوك القطن في ذكور الجرذان المعالجة برابع كلوريد دراسة فسيولوجية ومناعية لتأثير زيت بذور الكاربون

حسني عبدالله محمد*, مليكة قاسم نجيب, اماد محمد صالح جبرائيل

قسم علوم الحياة, كلية العلوم, جامعة دهوك, دهوك, العراق

الخلاصة

في هذه الدراسة، تم التركيز على التأثيرات الوقائية للزيت المستخلص من بذور *Onopordum acanthium* L. (شوك القطن) المحلية بجرعة (0.5 مل/كغم) ضد تلف الأنسجة في الكبد والكلى والطحال.

*Email: amad.sofi@uod.ac

في ذكور الجرذان البيضاء. تم تقسيم أربعين من ذكور الجرذان بشكل عشوائي إلى أربع مجموعات متساوية تشمل: مجموعة السيطرة، الفئران المعالجة بزيت بذور الشوك القطني فقط، المجموعة المحقونة برابع كلوريد الكربون، وفي المجموعة الأخيرة تم تجريع الفئران برابع كلوريد الكربون وعولجت بزيت البذور. بعد مرور 4 أسابيع من التجربة، تم تخدير الجرذان وأخذ الدم مباشرة عن طريق ثقب القلب لتقييم المعايير المدروسة. تم تثبيت عينات الكبد والكلى والطحال في الفورمالين بنسبة 10% للدراسات النسيجية.

من خلال النتائج التي تم الحصول عليها، لم يلاحظ أي تغييرات معنوية في جميع المعايير المقدر في الفئران المعالجة بالزيت فقط. في المجموعة المحقونة برابع كلوريد الكربون والمعالجة بزيت المستخلص، انخفضت مستويات كل من دهون المصل، وإنزيمات الكبد، وبيليروبين المصل الكلي (TSB)، وعامل نخر الورم ألفا (TNF- α)، والبروتين التفاعلي (CRP)، وخلايا الدم البيضاء (WBCs) بشكل معنوي بالمقارنة بمجموعة رابع كلوريد الكربون الغير معالجة. تم تحسين سمية رابع كلوريد الكربون على مستوى مستوى السكر الدم الصائم (FBS) و الإنزيم المحول للأنجيوتنسين (ACE) والبروتين الدهني عالي الكثافة (HDL) و معايير وظائف الكلى ونسبة الهيموجلوبين و وزن الجسم عند معالجتها بزيت البذور. دعمت هذه الأبحاث الفعالة للزيت المستخلص من خلال تحسن التغيرات النسيجية المرضية في أنسجة الكبد والكلى والطحال للفئران ضد سمية رابع كلوريد الكربون عند المعالجة بزيت البذور. الاستنتاج: من خلال نتائج هذه الدراسة يمكن الاستنتاج أن الزيت المستخرج من بذور *Onopordum acanthium* L. العراقية المحلية يقلل من تلف الأنسجة مع تحسن كبير في المعايير البيوكيميائية و الدموية والمناعية خلال اربعة اسابيع من التجربة.

Introduction

Several toxins are able to affect tissues in the vital organs such as the liver and kidney causing variable structural damages that lead to planned events such as cellular necrosis, apoptosis, autophagy, mitochondrial defects, inflammation and immune responses. The first inflammatory responses is the release of TNF- α , as a main component of the immune-mediated inflammation, and injury in acute and chronic conditions that regulate some physiological and pathological processes such as differentiation, development, apoptosis and cell death [1-2]. Chemicals that cause liver injuries are called hepatotoxins [3] such as CCl₄ that has been frequently used in experimental rodent animals for inducing liver damage [4]. It has been recently reported, that in addition to the liver, CCl₄ can induce damages in other organs such as the kidney and spleen [5-6]. However, this deterioration can be avoided naturally by some essential oils obtained from different plants [7].

In folk medicine, some plants were found to be effective in certain disorders. It is based on experience in the use of plant products or consumption as food that contain various compounds which can protect the body against common diseases. Therefore, herbal remedy has become increasingly popular, and many patients with liver disease use these botanicals [8-9]. *Onopordum acanthium* L. that is known as cotton thistle or Scotch thistle is one of the important genera within the family Asteraceae which is widely distributed over the world with long traditional uses [10]. Some experimental studies revealed its antioxidant, ACE inhibitory and hypotensive effects, Besides the ability to activate natural killer cells against tumor cells [11-12]. Moreover, the cotton thistle becomes interesting as an important novel commercial crop with multiple uses [13]. Its seeds oil has been used for cooking, burning and biodiesel production [14]. Cotton thistle seeds contain 12.35% of fat and major components of fatty acids such as linoleic, oleic, palmitic and stearic acids [15]. However, the role of seed oil has not been well identified yet. Therefore, in this study we evaluated the role of local *Onopordum acanthium* L. seeds oil against intoxicated tissues by CCl₄ by monitoring some important biochemical, hematological and immunological parameters with histopathological examination of liver, kidney and spleen during four weeks of the experiment.

Materials and methods

Animal and housing:

Animals were acclimated to the laboratory conditions for 10 days then mixed for breeding in the animal house, Department of Biology, College of Science, University of Duhok. The animals were placed in clean white ventilated polypropylene cages (30×25×17cm). Four rats were put in each cage with free access to standard diet and water under ethical and standard laboratory conditions (12h light: 12h dark photoperiod, at 24±2°C) with a frequent changing of cages bedding [16]. Adult males weighing 160-166gm were used for the experimental study.

Collection and identification of the plant species:

Plant seeds were collected locally during ripening season (June 2019) in Duhok City. The dry ripped seeds were ground in a coffee grinder for 5min, and the powdered seeds were stored in a clean glass container in a dark place until the time of the experiment. The plant was authenticated and morphologically described by Professor Dr. Saleem E. Shahbaz, Ataxonomist at the College of Agriculture Engineering Science, Department of the Forestry, University of Duhok.

Oil extraction:

Dry powder seeds (40g) were placed in a clean thimble tube and inserted into the sohxlet apparatus (Bionics- India). N-hexane (Scharlau-Spain) solvent (200ml) was poured into a bottom flask that was joined with sohxlet. A flask was connected along on the top with the condenser. The bottom flask containing solvent was placed in an electronic water bath heating (Eyela-UK) with controlled temperature (67°C) for 24hrs. Cold water was allowed to continually drain into the upper flask avoiding the evaporation of the solvent. At the end of extraction time, the mixture of solvent and oil were separated by a rotary evaporator (Eyela-UK) under a vacuum at a temperature of 47°C. Using sohxlet, fresh oil was daily extracted for the use in the experiment. The average of obtained oil after evaporation was weighted and calculated according to the equation used previously [17].

$$\text{Oil yield (wt\%)} = \frac{\text{Mass of extracted seed oil}}{\text{Mass of powdered seeds}} \times 100$$

Injection of CCL₄:

Twenty rats were intoxicated with CCL₄ (Riwdel-De Haen, Germany) 1.0 ml/kg/bodyweight of CCL₄ mixed with 1:1 of olive oil (vehicle) twice a week via intra-peritoneal injection [5].

Standard diet:

Standard diet contents for 1kg: wheat 665.5g, soya 256.2g, oil sunflower 43.5g, limestone 14.9g, Ca₂(PO₄) 6.42, salt 6.34g, lysine 2.44g, methionine 1.56g, enzymes 0.8g, choline chloride 0.62g, vitamins 0.58g, and trace elements 0.5g [18].

Experimental Designs:

After the adaptation period, forty male rats were randomly divided into four equal groups, and the seeds oil was orally administrated (0.5 ml/kg) during 4 weeks as follows:

Group 1: Rats were fed a standard diet and were served as a normal control group.

Group 2: Rats were fed a standard diet and were treated with seeds oil only.

Group 3: Rats received CCL₄ (1.0 ml/kg) and served as the untreated CCL₄ group.

Group 4: Rats intoxicated with CCL₄ (1.0 ml/kg) and were treated with seeds oil.

Hematological analysis

On the last day of the experiment, rats were deprived of food overnight with free access to water. Animals were anesthetized with diethyl ether (Scharlab S.L-Spain). 7 ml of blood samples were obtained directly by heart puncture in which 2 ml of blood was collected in

heparinized tubes (Arzer Grande- Italy) for the determination of hematological parameters by using an automated Hematological analyzer (Horiba-France).

Estimation biochemical

To obtain serum, 5ml of blood was placed in sterile gel tube (Arzer Grande- Italy) and was allowed to clot for 30 minutes before centrifugation at 4000 rpm for 15 minutes. Biochemical parameters such as FBS, serum lipids, renal, liver function tests and ACE were estimated by Cobas 600(C501) automated chemistry analyzer (Roche/Germany). The estimated tests were measured according to their kits procedures (Roche/Germany) that depended on the absorbance photometry (enzymes, substrates and specific proteins).

Estimation of Tumor Necrosis Factor Alpha (TNF- α):

TNF- α was determined by enzyme-linked immunosorbent assay according to steps in the kit (Mybiosource- USA).

Histopathological study:

After the dissection animals, sections of liver, kidney and spleen were immediately removed and cleaned with distilled water, and were fixed in 10% formalin. After processes of dehydration with ethanol, xylene clearing agent and fixing with paraffin wax, thin sections (4 μ M) were stained with haematoxylin (H) and eosin (E) (Atom Scientific-England) by using Auto Staining Apparatus (Leica/Germany). The mounted slides were identified by a light microscope (Olympus/Japan) and the pointed field was taken by a specialized camera (Dino-Taiwan) connected with the microscope [19].

Ethics:

The study protocol was signed by the scientific committee of the Biology Department, College of Science, University of Duhok.

Statistical analysis:

Data was analysed statistically by Microsoft Excel 2010 and GraphPad Prism 5 (California- USA) using analysis of variance (ANOVA) followed by Tukey test. Firstly, all groups were compared with the control group (pointed as *) and then the intoxicated rats with seeds oil treatment, were compared to the untreated intoxicated group (pointed as capital letters; A, B, C, and D). Results were expressed as mean \pm standard errors. P-values < 0.05 were considered statistically significant values. Each letters represent significant values as follow: A = non-significant, B = (P < 0.05), C = (P < 0.01), and D = (P < 0.001).

Results

The results represent the impact of extracted seeds oil on tissue damaged in rats on blood glucose and serum lipids:

FBS and serum lipids showed no obvious changes in rats treated with cotton thistle oil only as compared to the control group. The level of serum lipids (P<0.001) and FBS (P<0.05) were significantly higher in the treated CCl₄ group in comparison with the control group. However, the level of low-density lipoprotein (LDL) significantly (P<0.05) reduced. Triglycerides (TG), very low density-lipoprotein (VLDL) levels became significantly (P<0.001) more improved in the intoxicated rats treated with seed oil as related to the untreated liver damaged rats (Figure3-1). The significant (P<0.01) decreased level of HDL in the group having CCl₄ significantly (P<0.01) increased with oral administration of seeds oil.

Table 3-1-Effect of onopordum oil on glucose level and serum lipids

Groups Parameter	Control	Oil extract	CCl ₄	CCl ₄ + Oil extract
Glucose mg/dl	112.1 \pm 4.37	118.6 \pm 4.81	150.1 \pm 3.49* A	137.4 \pm 2.42A
Cholesterol mg/dl	57.50 \pm 2.46	54.90 \pm 4.28	73.77 \pm 2.73**A	69.46 \pm 3.80A
TG mg/dl	59.13 \pm 3.043	59.80 \pm 3.447	103.8 \pm 4.99***A	71.8 \pm 1.96D

HDL mg/dl	28.0 ±0.88	25.80±1.890	20.13±1.35**A	28.89±0.79C
VLDL mg/dl	11.83±0.60	11.96±0.6895	21.05±1.90***A	13.89±0.46D
LDL mg/dl	15.17±0.55	15.55±1.068	24.45±1.33***A	16.93±0.67B

Values are mean ± SE, *= (P< 0.05), **= (P< 0.01), ***= (P< 0.001) for comparison all groups with control group Renal and liver function parameters, ACE level and body weight:

As shown in (Table 3.2), serum levels of urea, creatinine, ACE and serum proteins significantly increased in the untreated CLL4 group and ameliorated almost toward the level of the control group when treated with cotton thistle oil. The significant (P<0.001) high level of aspartate transaminase (AST), alanine aminotransferase (ALT), alkaline phosphatase (ALP), gamma-glutamyl transferase (GGT) and TSB in the group received CCL4 significantly (P<0.001) improved with administration of seed oil (Figure 3.1). The significant (P<0.001) reduction of the final body weight (FBW) in CCL4 injected group improved with oil treatment but statistically was non-significant. up. Capital letters represent comparison between intoxicated groups.

Table 3.2- Effect of seeds oil on renal and liver function parameters, ACE and body weight

Groups Parameter	Control	Oil extract	CCL₄	CCL₄+ Oil extract
Urea mg/dl	35.81±0.92	32.70±1.26	48.52 ± 1.39**A	38.20±2.87A
Creatinine mg/dl	0.36±0.019	0.32±0.016	0.56±0.03***A	0.45±0.024A
AST (GOT) IU/L	123.6±2.03	124.6±4.91	337.0±7.37***A	243.0±7.67***D
ALT (GPT) IU/L	38.63±1.38	34.50±0.76	208.5±4.74***A	153.3±2.31***D
ALP IU/L	179.2±11.28	172.4±3.21	334.0±14.50***A	267.0±14.94***D
GGT IU/L	1.56±0.16	2.80±0.42	20.22±2.36***A	12.09±0.34C
TSB mg/dl	0.18±0.016	0.16±0.013	0.72±0.06***A	0.19± 0.019C
Total Protein g/dl	6.54±0.11	6.06±0.072	5.6±0.058***A	6.11± 0.072A
Albumin g/dl	3.64±0.02	3.60±0.098	3.19±0.11*A	3.47±0.097A
Globulin g/dl	2.89±0.11	2.70±0.08	2.36± 0.06*A	2.65± 0.09A
ACE U/L	192.1±3.90	186.7±2.48	210.3±3.47*A	203.2±1.71A
FBW (g)	304.3±2.1	294.2±7.29	217.4±1.67***A	223.7±4.16***A

Values are mean ± SE, *= (P< 0.05), **= (P< 0.01), ***= (P< 0.001) for comparison all groups with control group. Capital letters represent comparison between intoxicated groups.

Some immunological and hematological parameters:

TNF- α level in the group treated only with CCL4 significantly (P<0.001) increased while it became significantly (P<0.001) lower with seeds oil treatment (Figure 3.1, d). The level of serum CRP was significantly increased (P<0.001), and significantly (P<0.05) improved with co-treatment of seed oil (Figure 3.1, E). The significant (P<0.001) increase of WBCs (Figure 3.1, E) and monocytes% (P<0.05) in the treated CCL4 group improved significantly (P<0.05), (P<0.001) in respectively when treated with oil in comparison with the untreated liver damaged rats. Granulocyte and lymphocyte %ages in all groups showed no significant changes in comparison with the control group.

Hemoglobin decreased significantly (P<0.05) in the group that received CCL4 and was improved with oil treatment. In other groups, no significant changes were observed in hematological parameters in comparison with the control group.

Table 3.3-Effect of onopordum oil on some immunological and hematological parameters

Groups Parameter	Control	Oil extract	CCL ₄	CCL ₄ + Oil extract
TNF- α pg/ml	7.85 \pm 1.12	7.652 \pm 0.99	35.07 \pm 1.86***A	18.79 \pm 1.01D
CRP mg/l	0.149 \pm 0.02	0.1445 \pm 0.01	6.02 \pm 0.24***A	5.08 \pm 0.06***B
WBC (x10 ⁶ /mm ³)	8.32 \pm 0.61	8.15 \pm 0.7	12.89 \pm 0.58***A	9.14 \pm 1.04D
Granulocyte %	8.88 \pm 0.94	8.150 \pm 0.70	12.03 \pm 0.67A	9.140 \pm 1.01A
Lymphocyte%	80.40 \pm 1.74	79.21 \pm 0.41	73.81 \pm 3.44A	83.45 \pm 3.26A
Monocytes%	10.74 \pm 0.86	9.84 \pm 0.53	14.62 \pm 1.13*A	9.37 \pm 0.39B
RBC (x10 ⁶ /mm ³)	6.41 \pm 0.52	6.39 \pm 0.13	6.25 \pm 0.58A	6.50 \pm 0.36A
Hb (g/dL)	13.3 \pm 0.08	13.29 \pm 0.09	12.4 \pm 0.21*A	12.95 \pm 0.15A
PCV (%)	41.4 \pm 0.41	40.50 \pm 0.65	38.9 \pm 0.64A	40.18 \pm 0.89A
MCV (fL)	57.1 \pm 1.76	55.90 \pm 1.59	53.2 \pm 1.44A	55.59 \pm 1.49A
MCH (pg)	18.7 \pm 0.77	18.76 \pm 0.73	15.1 \pm 0.35A	16.78 \pm 0.34A
MCHC (g/dL)	32.8 \pm 0.6595	33.88 \pm 0.44	30.1 \pm 0.38A	30.69 \pm 0.27A
Platelets (10 ³ /mm ³)	568.6 \pm 15.02	567.6 \pm 16.87	513.6 \pm 26.91A	563.5 \pm 46.80A

Values are mean \pm SE, *=(P< 0.05), **=(P< 0.01), ***=(P< 0.001) for comparison all groups with control group. Capital letters represent comparison between intoxicated groups.

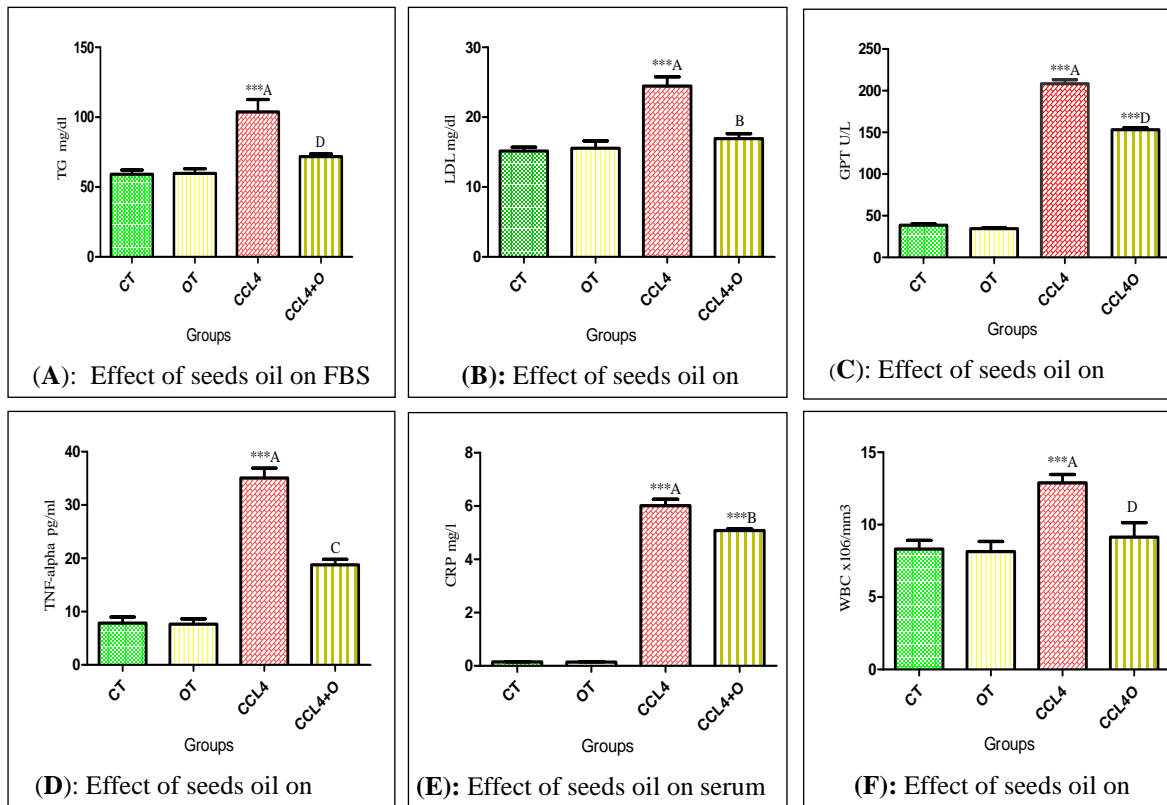


Figure 3.1-Effective role of cotton thistle seeds oil on some serum parameters, in which * = comparison of all groups with control group, capital letters = comparison between intoxicated

groups. CT = control, OT = oil extract, CCL₄ = carbon tetrachloride, CCL₄+O.= carbon tetrachloride + oil. Significance values is shown as *** (P<0.001), ** (P<0.01), * (P<0.05).

Histological examination of the kidney, liver, and spleen:

Kidney

In the group treated with seed oil only (Figure 3.2 B), kidney sections revealed the almost normal histological appearance of glomeruli and renal tubules as in the control group (Figure 3.2 A). Kidney sections in the group treated with CCL₄ only (Figure 3.2 C) showed variable damages through congestion, dilation, and hemorrhage in glomeruli, focal necrosis of epithelial tissues that line the renal tubules. In the group receiving CCL₄ and treated with seeds oil (Figure 3.2 D), kidney damage was reduced by improving degeneration, hemorrhage, and necrosis in glomeruli, and renal tubules.

Liver

Liver sections in control (Figure 3.3 A), and oil-treated rats (Figure 3.3 B), showed normal structures of hepatic lobules. On the contrary, liver of rats intoxicated with CCl₄ (Figure 3-3 C), showed various pathological alterations such as congestion, hemorrhage and necrosis in the central vein, and hepatocytes with variable degrees of inflammatory infiltrations cells. However, damages were reduced, and in some sections recovered, when treated with seed oil (Figure 3.3 D) by decreasing of hemorrhage, congestion, necrosis, and other toxicity of CCl₄ on liver tissues.

Spleen

In the control group (Figure 3.4 A), and rats treated with oil only (Figure 3.4 b), spleen sections showed no pathological histological alterations in white pulps, red pulps and central arterioles. In the group intoxicated with CCl₄ only (Figure 3-4 c), spleen sections showed obvious changes in the structure of pulps through scattered necrotic areas and apoptotic changes in the parenchymal tissue with fragmented nuclei. The spleen of CCl₄-intoxicated rats treated with seeds oil (Figure 3.4 D) showed reduction and recovering of injured tissue with almost normal structural of parenchymal cells with decreasing apoptosis, and necrosis.

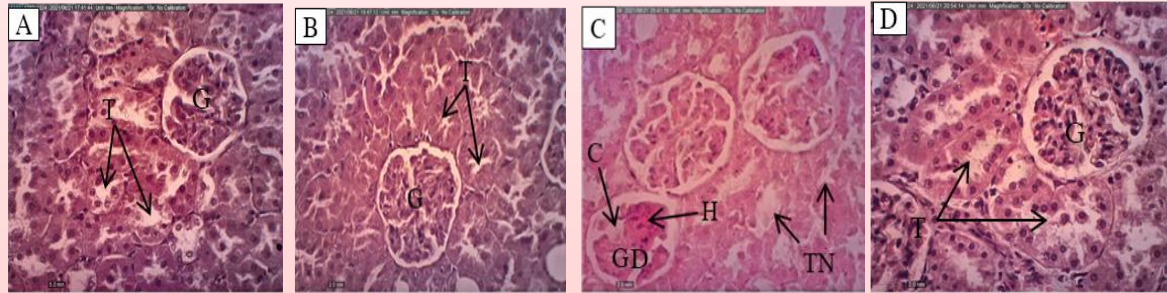


Figure 3.2-cross sections of kidney at 20x magnifications (H&E): control group (A), and group treated with oil only (B) showing normal glomeruli (G), and renal tubules (T). (C): Cross section of kidney in CCL4 injected group showing various lesions such as glomerulus degeneration (GD), haemorrhage (H), congestion (C) in glomeruli, and renal tubules with tubular necrosis (TN). (D): Cross section of kidney in CCL4 intoxicated group, and treated with oil extract showing almost recovering in some cases, and reduction of renal damage in glomerulus, and renal tubules.

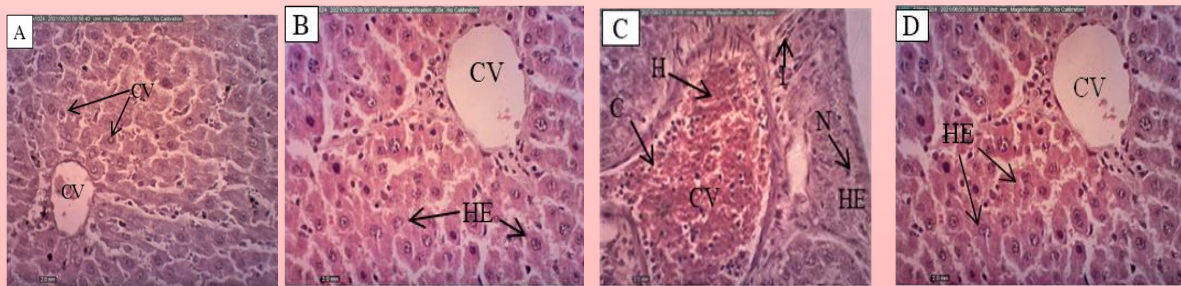
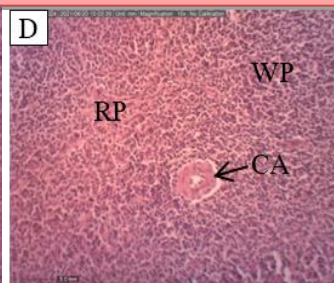
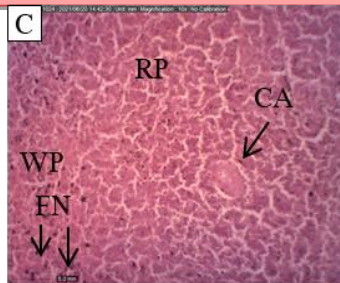
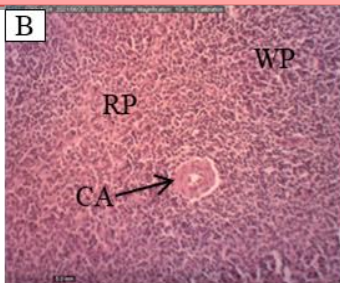
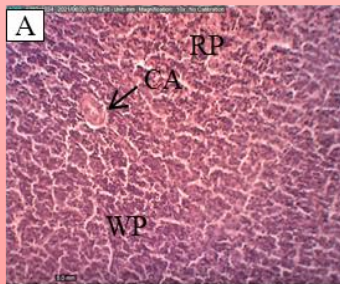


Figure 3.3-cross sections of liver at 20x magnifications (H&E): control group (A), and treated group with oil only (B) showing normal central vein (CV), and hepatocyte (HE). (C): Section of intoxicated liver showing congestion (C), and haemorrhage (H) in the central vein, disruption, and necrosis (N) in hepatocytes, and aggregation of inflammatory cells (I). (D): Section of liver in CCL₄-intoxicated rats treated with seeds oil showing decreased congestion, haemorrhage, and necrosis.



Discussion

CCl_4 has been reported as a potent hepatotoxic agent that is widely used in experimental studies for screening of the protective role of some drugs and medicinal plants against liver damages [20]. Moreover, in addition to liver injury, CCl_4 induces various damages in other organs such as the kidney and spleen damage via overproduction of free radicals [21]. Under the activity of the oxygenase system, the cytochrome P450 in the endoplasmic reticulum converted CCl_4 to trichloromethyl radical which in turn reacts with oxygen to form trichloromethyl proxy radical. These radicals are highly reactive and can also bind to various cellular molecules such as lipids, fatty acids, proteins, amino acids and nucleic acids, leading to the initiating of chain reactions such as lipid peroxidation, which attacks and disrupting polyunsaturated fatty acids; particularly those that are associated with phospholipids [3, 22]. These damages further lead to various tissue injuries such as cellular necrosis, apoptosis, depletion of antioxidants, and progression of many acute, and chronic diseases, and activation of the immune system [23-24]. Therefore, liver intoxication by CCl_4 results from oxidative stress that usually causes an imbalance between reactive oxygen species (ROS) production and antioxidant defense system., in which antioxidant activity, and prevention of the production of free radicals are important sources for reducing the toxicity of CCl_4 on liver tissues [25].

In this study, the toxicity of CCl_4 in rats was manifested by an increase in the level of liver enzymes, serum lipids, $\text{TNF-}\alpha$, CRP, WBC, ACE, urea and creatinine with decreased serum proteins, hemoglobin and FBW constituent with histopathological changes in the liver, kidney and spleen tissues. These results have been supported previously [6]. The detection of elevated level of serum aminotransferases is mostly indicated as abnormal liver function existing in the hepatic cells which indicates structural changes in the hepatic tissues and biliary system [27]. These enzymes are located in the cytoplasmic and are certainly released in a large quantity into the peripheral blood during cellular damages of hepatic tissues [28-29]. Moreover, CCl_4 has been reported for inducing kidney damage in rats with remarkable leakage of proteins due to the hyper-cellularity of renal glomeruli, and tubules which leads to the reduction in the level of serum albumin. Furthermore, chronic inflammation and tissue injuries cause over-secretion of inflammatory mediators, including $\text{TNF-}\alpha$ ACE with decreasing activities of antioxidant enzymes that are sensitive to severe damage to the cells [3, 30-31]. $\text{TNF-}\alpha$ is considered as the main hepatotoxic mediator during liver injury [32] therefore, the release of $\text{TNF-}\alpha$, as a pro-inflammatory mediator during liver injury, is also linked to cytotoxicity induced by CCl_4 [33].

The total oil in *Onopordum acanthium* L. seeds in the current study was 11.12%. Its chemical composition has been identified, and analysed previously showing that it mainly contains linoleic, oleic, palmitic and stearic acids [15,34]. It has been reported that cotton thistle extracts have antioxidant and ACE inhibitory properties [35-37]. The exact mechanism between the inhibitor and ACE is not fully interpreted. Some studies concluded that agents blocking or inhibiting the activity of ACE can reduce blood pressure in hypertensive patients [38-39]. Furthermore, the activation of renin-angiotensin system is characterized by the increase in ACE expression that catalyzes the conversion of inactive angiotensin I to a bioactive angiotensin II which in turn exerts a variety of effects, importantly vasoconstriction and enhancing aldosterone. It has been reported that the crude oil of cotton thistle seeds is rich in a polyphenol by-product; α -tocopherol with potent free-radical removers that can be used as an anti-inflammatory and anti-carcinogenic agent against cancer cells. This has been further indicating that the *onopordum* plants gain new botanical sources that could provide useful therapeutic treatment for liver and oxidative stress-related diseases. Moreover, it has been considered that the use of cotton thistle compounds in food industry as a potential and cheap, saves the source of antioxidant components [41-42] against tumors and various other

chronic inflammations [43]. Therefore, the hepatoprotective activity of onopordum oil was well speculated in our study through ameliorating liver damage markers that could be mostly due to the presence of antioxidant activity. On the other hand, the improvement level of TNF- α , CRP and WBC as signs of inflammation, with better kidney functions, can be other additional factors. Moreover, these results can be correlated with those of Han et al. (2019) in which they reported that the significant hepatoprotective effect of plant seed extracts have been suggested due to downregulation of cytokines such as TNF- α in treated animals [44]. This further indicates that the extracted oil can alleviate CCl₄-induced tissue damages to a certain extent and is consistent with the histopathological results.e secretion [40].

Conclusion

The oral administration of seeds oil from local *Onopordum acanthium* L. was effective in the controlling of abnormal biochemical, immunological and haematological parameters in the rats intoxicated with CCl₄ constituent with the improvement of damages in the liver, kidney and spleen tissues.

References:

- [1] V. Baud and M. Karin, "Signal transduction by tumor necrosis factor and its relatives," *Trends in cell biology*, vol. 11, no. 9, pp. 372-377, 2001.
- [2] H. Howerton and S. T. Tarzami, "Tumor Necrosis Factor-alpha and inflammation-mediated cardiac injury," *J. Cell Sci. Ther*, vol. 8, pp. 1-4, 2017.
- [3] L.W.D. Weber, M. Boll and A. Stampfl, "Hepatotoxicity and mechanism of action of haloalkanes: carbon tetrachloride as a toxicological model," *Critical reviews in toxicology*, vol. 33, no. 2, pp.105-136, 2003.
- [4] M. Parola, G. Leonarduzzi, F. Biasi, E. Albano, M. E. Biocca, G. Poli and M. U. Dianzani, "Vitamin E dietary supplementation protects against carbon tetrachloride-induced chronic liver damage and cirrhosis," *Hepatology*, vol. 16, no.4, pp. 1014-1021, 1992.
- [5] B. R. Dabdoub, R. H. Mohammed and H. L. Abdulhadi, "Ganoderma lucidum attenuates and prevents CCl₄-induced hepatic and renal damage in Sprague-Dawley Rats," *Systematic Reviews in Pharmacy*, vol. 11, no.12, pp. 1704-1709, 2020.
- [6] E. A. Sayed, G. Badr, K. A. Hassan, H.Waly, B. Ozdemir, M.H.Mahmoud, S. Alamery, "Induction of liver fibrosis by CCl₄ mediates pathological alterations in the spleen and lymph nodes: The potential therapeutic role of propolis," *Saudi Journal of Biological Sciences*, vol. 28, no.2, pp.1272-1282, 2021.
- [7] N. E. Daoudi and M. Bnouham, "Hepatoprotective Essential Oils: A Review," *Journal of Pharmacopuncture*, vol. 23, no. 3, pp. 124, 2020.
- [8] P. V. Kumar, A. Sivaraj, E. K. Elumalai and B. S. L Kumar, "Carbon tetrachloride-induced hepatotoxicity in rats-protective role of aqueous leaf extracts of *Coccinia grandis*," *Int J Pharm Tech Res*, vol 1, no.4, pp. 612-15, 2009.
- [9] H. S. Abou Seif, "Physiological changes due to hepatotoxicity and the protective role of some medicinal plants," *Beni-suef University journal of basic and applied sciences*, vol. 5, no.2, pp.134-146, 2009.
- [10] P. Cavers, M. Qaderi, P. Threadgill and M. Steel, "The biology of Canadian weeds. 147. *Onopordum acanthium* L.," *Canadian Journal of Plant Science*, vol. 91, no. 4, pp.739-758, 2011.
- [11] N.M. Abuharfeil, A. Maraqa and V.S. Kleist, "Augmentation of natural killer cell activity in vitro against tumor cells by wild plants from Jordan," *Journal of ethnopharmacology*, vol. 71, no. 1-2, pp. 55-63, 2000.
- [12] Y. Kiselova, D. Ivanova, T. Chervenkov, D. Gerova, B. Galunska and T. Yankova, "Correlation between the in vitro antioxidant activity and polyphenol content of aqueous extracts from Bulgarian herbs," *Phytotherapy Research: An International Journal Devoted to Pharmacological and Toxicological Evaluation of Natural Product Derivatives*, vol. 20, no.11, pp. 961-965, 2006.
- [13] M. A. Oueslati, A. Gunenc, G. Rigane, H. Ghazghazi, et al., "Chemical composition, antioxidant and cytotoxic activities of *Onopordum acanthium* L. Crude oil and defatted meal," *Rev. Roum. Chim*, vol. 64, no.6, pp.503-510, 2019.

- [14] K. M. Dobrivoje, J. M. Nataša, S.S. Olivera and V.B. Vlada, "The biodiesel production from the cotton thistle seed oil (*Onopordum acanthium* L.)," *Savremene tehnologije*, vol.3, no.2, pp. 35-45, 2014.
- [15] D. I. DyulgeRovA and A. StoyAnovA, "Lipid Composition of *Carduus thoermeri* Weinm., *Onopordum acanthium* L. and *Silybum marianum* L., growing in Bulgaria," *Bulgarian Journal of Agricultural Science*, vol. 20, no.3, pp.622-627, 2014.
- [16] A. Azzawi, A. F. Sameer and A. H. Baraaj, "Histological and Biochemical study of *Nigella Sativa* Seeds effects on Liver of male Albino Rats treated with Rifampicin," *Iraqi Journal of Science*, vol. 57, no.4C, pp. 2829-2839, 2016.
- [17] A. Bokhari, L. F. Chuah, S.Yusup, J. Ahmad and H. Aziz, "Kapok seed oil extraction using soxhlet extraction method: optimization and parametric study," *Australian Journal of Basic and Applied Sciences*, vol. 9, no.37, pp.429-431, 2015.
- [18] N. R. Council, "Nutrient requirements of laboratory animals, Fourth Revised Edition, 1995.
- [19] S. M. M. Razooki and A. M. Rabee, "Evaluation of the Toxicological Effects of Zinc Oxide Nanoparticles in Albino Male Mice," *Iraqi Journal of Science*, vol. 16, no. 1, pp. 42-58, 2020.
- [20] A. H. Adebayo, O. F. Yakubu and T. M. Balogun, "Protective properties of *Citrullus lanatus* on carbon tetrachloride induced liver damage in rats," *European journal of medicinal plants*, vol. 4, no. 8, pp. 979-989, 2014.
- [21] H. M. Reza, A.T. Sagor and A. Alam, "Iron deposition causes oxidative stress, inflammation and fibrosis in carbon tetrachloride-induced liver dysfunction in rats," *Bangladesh Journal of Pharmacology*, vol. 10, no.1, pp.152-59, 2015.
- [22] Z. Gao, F. Yuan, H. Li, Y. Feng, Y. Zhang, C. Zhang, J. Zhang, Z. Song and L. Jia, "The ameliorations of *Ganoderma applanatum* residue polysaccharides against CCl₄ induced liver injury," *International journal of biological macromolecules*, vol.137, pp.1130-1140, 2019.
- [23] M. Makni, Y. Chtourou, E. M. Gatoui, T. Boudawara and H. Fetoui, "Carbon tetrachloride-induced nephrotoxicity and DNA damage in rats: protective role of vanillin," *Human & experimental toxicology*, vol. 31, no.8, pp.844-852, 2012.
- [24] H. Barry and J. M.C. Gutteridge, "Free radicals in biology and medicine," *Oxford university press, USA*, 2015.
- [25] B. Patwardhan, A. D.B. Vaidya and M. Chorghade, "Ayurveda and natural products drug discovery," *Current science*, vol.86, no. 6, pp.789-799, 2004.
- [26] P. Muriel and Y. R. Espinoza, "Beneficial drugs for liver diseases." *Journal of Applied Toxicology: An International Journal*, vol. 28, no.2, pp. 93-103, 2008.
- [27] S. S. Sokar, M. E.S. El-Sayad, M. E.S. Ghoneim and A. M. Shebl, "Combination of Sitagliptin and Silymarin ameliorates liver fibrosis induced by carbon tetrachloride in rats," *Biomedicine & Pharmacotherapy*, vol. 89, pp. 98-107, 2017.
- [28] C. H. Lee, S.W. Park, Y. S. Kim, S.S. Kang, J. A. Kim, S. H. Lee and S.M. Lee, "Protective mechanism of glycyrrhizin on acute liver injury induced by carbon tetrachloride in mice," *Biological and Pharmaceutical Bulletin*, vol.30, no.10, pp.1898-1904, 2007.
- [29] D. Gan, L. Ma, C. Jiang, M. Wang and X. Zeng, "Medium optimization and potential hepatoprotective effect of mycelial polysaccharides from *Pholiota dinghuensis* Bi against carbon tetrachloride-induced acute liver injury in mice," *Food and chemical toxicology*, vol.50, no.8, pp. 2681-2688, 2012.
- [30] Q. Huang, Q. Xie, C.C. Shi, et al., "Expression of angiotensin-converting enzyme 2 in CCL₄-induced rat liver fibrosis," *International journal of molecular medicine*, vol. 23, no.6, pp.717-723, 2009.
- [31] Y. Mahmoodzadeh, M .Mazani and L. Rezagholizadeh, "Hepatoprotective effect of methanolic *Tanacetum parthenium* extract on CCl₄-induced liver damage in rats," *Toxicology reports*, vol. 4, pp. 455-462, 2017.
- [32] L.J. Zhang, J. P. Yu, D. Li, Y. H. Huang, Z. X. Chen and X. Z. Wang, "Effects of cytokines on carbon tetrachloride-induced hepatic fibrogenesis in rats," *World journal of gastroenterology*, vol. 10, no.1, pp. 77, 2004.
- [33] Y. Diao, X. F. Zhao, J. S. Lin, Q. Z. Wang and R.A. Xu, "Protection of the liver against CCl₄-induced injury by intramuscular electrotransfer of a kallistatin-encoding plasmid," *World Journal of Gastroenterology: WJG*, vol. 17, no.1, pp. 111, 2011.

- [34] B. Maurizio, M. Antonella, R. Sergio, S. Muhammad and B. Svetlana, "The metabolites of the genus Onopordum (Asteraceae): Chemistry and biological properties," *Current Organic Chemistry*, vol. 15, no.6, pp. 888-927, 2011.
- [35] R. Ghods, M. Gharouni, M. Amanlou, N. Sharifi, A. Ghobadi and G. Amin, "Effect of Onopordon acanthium L. as add on antihypertensive therapy in patients with primary hypertension taking losartan: A pilot study," *Advanced pharmaceutical bulletin*, vol.8, no.1, pp. 69, 2018.
- [36] S. Habibatni, A. F. Zohra, H. Khalida, S. Anwar, I. Mansi and N. A. A. Ali, "In-vitro antioxidant, Xanthine oxidase-inhibitory and in-vivo Anti-inflammatory, analgesic, antipyretic activity of Onopordum acanthium," *Int. J. Phytomed*, vol. 9, pp. 92-100, 2017.
- [37] A. E. Al-Snafi, "Constituents and pharmacology of Onopordum acanthium," *IOSR Journal of Pharmacy*, vol. 202, no.10, pp.3, 2020.
- [38] C. Vickers, P. Hales, V. Kaushik, M. Patane, A. Nichols and P. Tummino, "Hydrolysis of biological peptides by human angiotensin-converting enzyme-related carboxypeptidase," *Journal of Biological Chemistry*, vol. 277, no.17, pp. 14838-14843, 2002.
- [39] G. Y. Oudit, A. M. Herzenberg and Z. Kassiri, et al., "Loss of angiotensin-converting enzyme-2 leads to the late development of angiotensin II-dependent glomerulosclerosis," *The American journal of pathology*, vol.168, no.6, pp. 1808-1820, 2006.
- [40] N. Sharifi, E. Souri, S. A. Ziai, G. Amin, M. Amini and M. Amanlou, "Isolation, identification and molecular docking studies of a new isolated compound, from Onopordon acanthium: A novel angiotensin converting enzyme (ACE) inhibitor," *Journal of ethnopharmacology*, vol. 148, no.3, pp. 934-939, 2013.
- [41] M. Naczek, R. B. Pegg, R. Zadernowski and F. Shahidi, "Radical scavenging activity of canola hull phenolics," *Journal of the American Oil Chemists' Society*, vol. 82, no.4, pp. 255-260, 2005.
- [42] J. Ju, S. C. Picinich, Z. Yang, Y. Zhao, N. Suh, A.N. Kong and C. S. Yang, "Cancer-preventive activities of tocopherols and tocotrienols," *Carcinogenesis*, vol. 31, no.4, pp. 533-542, 2010.
- [43] E. R. Garsiya, D.A. Konovalov, A. A. Shamilov, M. P. Glushko and K. K. Orynbasarova, "Traditional medicine plant, Onopordum acanthium L. (Asteraceae): chemical composition and pharmacological research," *Plants*, vol. 8, no.2, pp. 40, 2019.
- [44] C.Y. Han T.T. Sun, G.P. Xv, S.S. Wang, J.G. Gu and C.Y. Liu, "Berberine ameliorates CCl4-induced liver injury in rats through regulation of the Nrf2-Keap1-ARE and p53 signaling pathways," *Molecular medicine reports*, vol. 20, no.4, pp. 3095-3102, 2019.