



ISSN: 0067-2904

## Effect of maternal exposure of silver nanoparticles on the histogenesis of cerebellum in post-implantation of albino rats embryos

Esraa H. Ali\*, Lina A. Salih

Department of Biology, College of Science, University of Baghdad, Baghdad, Iraq.

### Abstract

The central nervous system is the most important system and is very sensitive to any accidental infection during ontogenesis; it includes brain and spinal cord. The cerebellum is the second largest part of the brain after cerebrum and it's very sensitive to the abnormal changes during the embryological development. This study was designed to investigate the effect of the maternal exposure of selected concentrations of suspension of nanoparticles on the ontogenesis of the rat cerebellum after embryos implanted in uterus.

A total of 60 female pregnant rats were divided in to three groups, each contains 20 females. Group1 (G1) was treated orally with 2mg/kg /body weight (b. wt) of suspension of silver nanoparticles (Ag NPs). While group 2 (G2) was treated with 20mg/kg/b. wt of AgNPs after implantation from 7<sup>th</sup> day of pregnancy until delivery at day 21<sup>st</sup> for 15 day. And group3 (G3) was considered as control whose received Distal water (D.W) only. We had selected the following embryonic day for treatment (ED12, 15, 18 and 21). The histological results showed a defect in the ontogenesis of the cerebellum cortex layers of embryos, through lack of density of external granular layer, as well as degeneration and dispersion of the glial cells in the internal granular layer of cerebellar cortex, in addition to less distribution of cells in the molecular layer due to the ability of AgNPs to pas the placenta and blood brain barrier (BBB) to the embryo's brain after female exposure to the AgNPs during pregnancy. AgNPs at low concentration 2mg/kg/day and higher concentration 20mg/kg/day can produce many histological toxicity to the embryo's hindbrain and cerebellum when administrated to the dams during pregnancy period.

**Key words:** silver nanoparticles, cerebellum, rats embryos.

## تأثير تعرض الامهات لدقائق الفضة المتناهية الصغر في التكوين النسيجي للمخيخ بعد انغراز اجنة الجرذان البيض

اسراء حسن علي\*، لينا عبد المطلب صالح

قسم علوم الحياة، كلية العلوم، جامعة بغداد، بغداد، العراق.

### الخلاصة

يعد الجهاز العصبي المركزي من اهم اجهزة الجسم واكثرها حساسية لاي حادث او اصابة خلال مرحلة التكوين النشوي، يضم هذا الجهاز الدماغ والحبل الشوكي ، ويحتوي الدماغ على المخيخ وهو الجزء الاكبر والاكثر حساسية للتغيرات الغير طبيعية خلال مرحلة التكوين الجنيني. صممت هذه الدراسة للتحري عن تأثير تعرض الامهات لتراكيز مختارة من عالق جزيئات الفضة المتناهية الصغر في التكوين النشوي لمخيخ اجنة الجرذان البيض بعد انغراز الاجنة في الرحم.تم اجراء الدراسة على 60 انثى حامل قُسمت الى ثلاث مجاميع

\*Email: esrahassan954@yahoo.com

كل مجموعته مؤلفة من 30 أنثى، المجموعة الأولى تم تجريعها فمويًا ب (2ملغم /كغم/ وزن الجسم) من عالق جزيئات الفضة المتناهية الصغر، المجموعة الثانية تم معاملةتها فمويًا ب (20ملغم /كغم/ وزن الجسم) من عالق جزيئات الفضة المتناهية الصغر ابتداءً من اليوم السابع من الحمل وحتى الولادة في اليوم 21 منه، أما المجموعة الثالثة فقد اعتبرت مجموعة السيطرة التي تمت معاملةتها ب الماء المقطر فقط. تم اختيار الأيام الجنينية (18, 15, 12 و 21)، أظهرت النتائج النسيجية تضرر في التكوين النشوئي لقشرة المخيخ للجنة من خلال انخفاض كثافة الطبقة الحبيبية الخارجية للقشرة وتشتت وانحطاط الخلايا الدبقية في الطبقة الحبيبية الداخلية لقشرة المخيخ، بالإضافة إلى انخفاض في توزيع الخلايا في الطبقة الجزيئية بسبب تمكن جزيئات الفضة المتناهية الصغر من عبور المشيمة وحاجز الدم في الدماغ للجنة بعد تعرض الأمهات لجزيئات الفضة المتناهية الصغر خلال الحمل. ويستنتج من هذه الدراسة أن جزيئات الفضة النانوية بتركيز واطئ (2ملغم/كغم/ اليوم) وبتركيز أعلى (20 ملغم/كغم/اليوم) يمكنها أن تسبب العديد من السمية النسيجية للدماغ الخلفي والمخيخ للجنة عند إعطائها إلى الأمهات خلال فترة الحمل.

## Introduction

The central nervous system (CNS) is a very critical and sensitive system during embryogenesis; it is protected by blood-brain barrier (BBB) which, consequently, hampers the success of current therapies by blocking drugs and other chemical and nanoparticles access to brain [1]. BBB is a layer of endothelial cells very tightly bound to each other (by tight junctions, TJ) that block the transport of drugs and many nanoparticles from blood to brain [2]. The cerebellum is the second largest part of the brain therefore, the cerebellum is an ideal useful model for studying many aspects of neural development, because each stage of development has a distinct morphology and special histological features with different types of cells [3]. The volume of the human cerebellum increases  $\sim 10\times$  between 20 and 40 weeks of gestation, with the surface area increasing much more due to the formation of folia and lobules [4], [5].

Physiologically, the cerebellum is considered as the key regulator of the central nervous system in the mammals, because it regulates the motor and sensory activities such as attention, balance, languages and some emotional functions like fear and pleasure [6], [7]

Because rapid development of nanotechnology has led to the wide application of nanoparticles (NPs) in various fields such as, catalysis and biotechnology including cosmetics, pharmaceuticals and medicines [8] However, there is a lack of information concerning the impact of NPs on human health, as it was proved that the nanoparticles could be administered to human body by several routes including inhalation, ingestion, dermal penetration, and injection, followed by the distribution of these nanoparticles to various tissues through systemic circulation [9]. The NP size is important in CNS penetration, with several studies suggesting a 20–70nm diameter as being optimal for transport; Surface charge can also facilitate NP-mediated BBB disruption. They also are at high risk of having brain disease such as Alzheimer's disease. This study aim to investigate the histological toxicity of Ag as nanoparticles on embryo's cerebellum in different embryonic age when dams exposure to these nanoparticles during embryonic development.

## Materials and methods

### Animal housing

In this study, 60 mature female Sprague-Dawley albino rats (*Rattus norvegicus*) were used. They were purchased from animal house of Iraqi national center for drug control and research. The average ages of females were 1.5-2 months age and their average ranged between 100 – 300g.

All animals were housed in plastic cages with a metal network cover under climate conditions, with temperature  $22\pm 2^\circ\text{C}$  and 12:12 light and dark cycle. Rats were provided with water and food *ad libitum*. Cages were cleaned and sterilized in different times with 70% ethanol. After mating, the gestational day zero was defined as the day when spermatozoa were observed in the smear taken from females' vagina, then females were transferred to separate cages without males and stayed there until the appropriate days to isolate the embryos [10].

Then, the females were divided in to three groups, (G1) received (2mg/kg/ B.wt AgNPs) (G2) received 20mg/kg/B.wt AgNPs and (G3); treated as a control group and was given D.W only. The

AgNPs solution was given orally by using polyethylene orogastric tubes connected to a hypodermic syringe with a volume of 1-2 ml.

#### Preparation Silver nanoparticles (AgNPs)

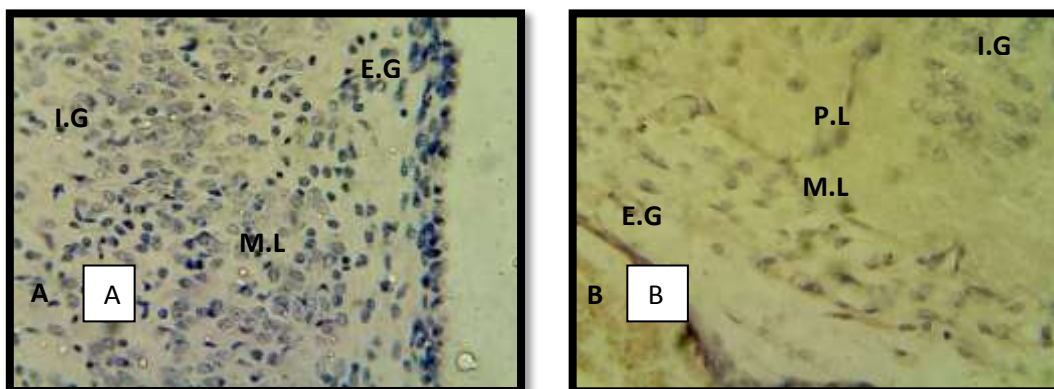
AgNPs they were purchased as grey black solid powder (purity 99.9%, apparent density: 0.97g /ml, tap density: 2.16 g/ml and CAS NO.: 7440-22- 4) with an average diameter of (40-59.71) nm, they were examined under scanning probe microscope. AgNPs was prepared at a two concentrations; low concentration of 2mg/kg of body weight and high concentration of 20mg/kg of body weight according to [11]. The AgNPs stock solution was prepared by suspending the AgNPs powder in a certain volume of deionized distilled water. The suspension was exposed to the ultrasonication technique by ultrasonic water bath for 2-3h in dark and under biological safety [12].

#### Embryos retrieved

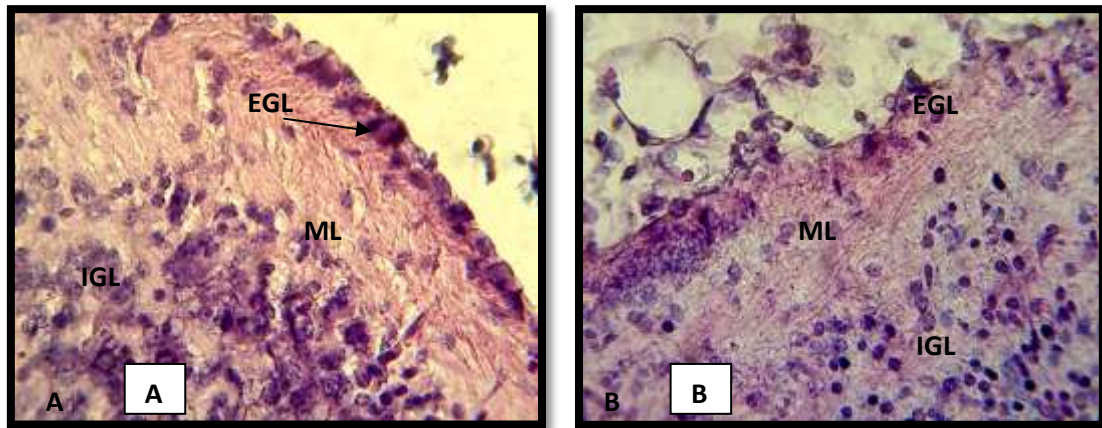
The pregnant female albino rats were fully anesthetized by diethyl ether for several minutes. The embryos were retrieved in different gestation days (GD12, 15, 18 and 21). In treated and control groups, abdominal midline incision was performed, the two uterine horns were exposed, the embryos were extracted from the placental sacs by hysterectomy, and the extra-embryonic membranes were then removed, rinsed in normal saline, then the embryo was examined under the dissecting microscope. The embryonic day ED12 transferred immediately to the Bouin's solution for fixation, embryos at ED15, 18 and 21 the skulls were removed by dissecting tools and cerebellum was isolated from brain carefully by incision along the dorsal aspect. All of the samples were fixed in the Bouin's solution for 24-48h and were transferred to 70% ethanol until the time of the histological sectioning according to [13].

#### Results

Serial sagittal sections of the cerebellum were taken from ED 12 to 21 days. The results of the control group in early development ED12 showed simple histogenesis of metencephalon anlage and cerebellum, represented by a slight thickness of external granular layer (EGL), cellular features in molecular layer, appearance of early purkinje cells layer and dense regular cell in the internal granular layer (IGL). later development (ED15-ED21) showed dense ependymal cells, appearance the mantle layer as well, the result showed dense EGL, and the appearance of glial cells in IGL were well developed at ED21, molecular layer, Purkinje layer and well differentiated IGL normal nerve fibers Figure-1(A, B). The results of sagittal sections of cerebellum of rat embryos in G1 at ED12 showed EGL, less cells in molecular layer and less cells in IGL in comparison with control group that appearance of normal rudiment cerebellar anlage at this stage. At ED15 the section showed less dense of EGL, fewer cells in molecular layer and the cells were dispersed in IGL. The histological section of embryo's cerebellum at ED18 revealed less cells and degenerative in EGL, less cellular elements of marginal layer and dispersed in the mantle layer. while, at ED21 the sagittal section showed EGL, less cellular in molecular layer and dispersed of cells in IGL when compared with control group. Figures- 2 (A, B, C, D).

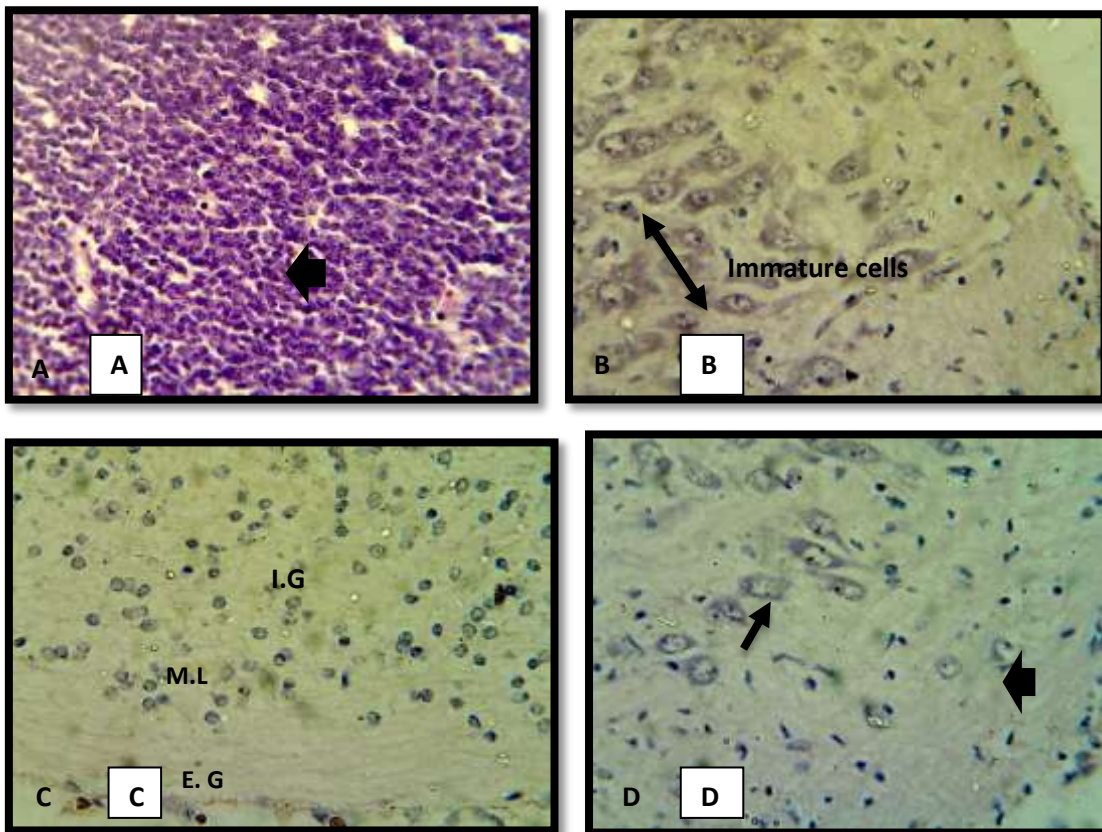


**Figure1-**Sagittal section of rat embryo's cerebellum of control group (H & E stain 400X)  
A- cerebellum anlage shows normal EGL : External granular layer, ML: Molecular layer, IGL : Internal granular layer at ED12,15 B-cerebellum shows EGL, ML, , PL :purkinje layer , IGL :Internal granular layer ED21



**Figure 2-** Sagittal section of rat embryo’s cerebellum treated with 2mg/kg/B.wt of AgNPs (H & E, 400X ) A-cerebellum anlage at ED 12 EGL:external granular layer M.L: molecular layer, I.G : IGL B-cerebellum at ED15 ML : molecular layer, dispersed in IGL .

The histological sections of cerebellum in G2 group at ED12 showed slight cells in molecular layer and low dense in IGL. Some sections showed apoptosis in IGL cells. While, the histological section at ED15 showed of immature cells in mantle layer. On the other hand, the sagittal histological sections at ED18 showed very few cells or absent EGL, no cells seen in molecular layer whereas there were dispersed cells of IGL, and very few migratory neuroblasts elements in molecular layer. ED21 the results showed less density of EGL comparing to control group, few cells in molecular layer and dispersed of IGL. Other sections showed apoptosis in molecular layer and appearance of degenerative purkinje’s cells Figure-3(A, B, C, D)



**Figure 3-**Sagittal section of rat embryo’s cerebellum treated with 20mg/kg/B.wt of AgNPs (H & E stains 400X) A- Section at ED12 shows apoptosis in IGL B- section at ED15 shows immature cells in mantle layer( ) C-section at ED18 shows I.G: IGL , E.G: EGL and M.L: molecular layer D-section at ED21 shows apoptotic in molecular layer( ), degenerative of purkinje cells.( )

## Discussion

The present study investigated the effects of different concentrations of AgNPs (2,20mg/kg/day) average diameter was (40-59.71nm), after implantation of embryos in the uterus, and detected the histological changes of the cerebellum at the end of embryogenesis. The results revealed obvious toxicity of AgNPs of embryos' brain because these nanoparticles can be absorbed, and then accumulated in the brain regions by passing through the (BBB) especially in early development of embryo when the barrier is not full formed, this may be cause of some histological changes which occur in the development of early cerebellum of the embryos mainly in the mothers who receive the AgNPs during pregnancy, finally leading to dysfunctions of (CNS). Recent studies revealed that engineering nanoparticles can pass the blood brain barrier (BBB) and accumulate within the brain [10][14]. The BBB is a well protective structure, which is mainly composed of endothelial cells, astrocytes, and pericytes [15]. This barrier is capable of protecting the healthy and functional CNS from being affected by harmful chemicals, toxins, and drugs in the circulatory system, so any damage of this barrier respectively leads to brain tissue damage [16].

As a result, our findings showed that NPs induced inflammation, edema, and cell injury or even cell death in brain regions and tissue. Other study showed that after orally administration of TiO<sub>2</sub> NPS, the percentage of brain to body weight was down and the histopathological examination showed the presence of inflammatory cell aggregation and cells necrosis in the brain zones [17]. Additionally, the histological results revealed that AgNPs could enter to the embryo's brain and showed many damage in brain tissue, this may be due to NPs could not only pass the BBB but also disrupt the integrity of the BBB. Lin, *et al.*, suggested that 3–5 nm AgNPs can go into the nuclei of brain cells and alter the gene expression involved in immune response as well as cause DNA damage and apoptosis [18]. Our results showed AgNPs have much toxicity on brain tissue and cerebellum.

The thickness of the internal granular layer (IGL), molecular layer (ML) and the densities of granular and purkinje's cells were measured as described by [19]. The thickness of EGL became progressively thinner with treated and the results improved that these nanoparticles effected on migratory of proliferative cells during embryos development [20]. Many studies showed that (ROS) had the role of signaling molecules, could influence apoptosis and the activation of different signaling pathways. Other study found that after the entry of AgNPs to the cell, it can release silver ions and free radicals, which lead to an oxidative environment that can disturb the mitochondrial functions and neurotoxicity in brain tissue [21].

On the other hand, some researchers showed that the numbers of nonviable fetuses was significantly increased in dams treated to a single oral dose of 10 mg/kg/B.wt AgNPs not higher doses, this due to facilitation of aggregation AgNPs at higher concentration in gut and preventing internalization via the gastrointestinal tract and so reducing fetotoxicity at higher doses, this result agree with [22]. Other study showed many pathological changes in the brain structure in chicken embryos treated with platinum nanoparticles NP-Pt, showing a moderate degradation of the cerebellar molecular layer, loss in neural cells in the cerebellum cortex, and astrocytosis [23]. In this study, we observed that AgNPs when administration to pregnant rats at concentration (2, 20mg/kg/B.wt) not have seen mortality in dams, while, other study found that administration of 20 mg silver ion led to the death of more than half pregnant rats in group after 1 ml injection, due to that silver nanoparticle is less toxicity than silver ions [24]. Conversely, a great number of studies have already revealed that after pregnant mice or rats were exposed to some exogenous substances, such as nanoparticles, those substances could be detected in the brain of fetus and then they can disturb the homeostasis of CNS or even induce neuronal death [25]. Those hazard impacts on fetus brain have been demonstrated to be related with psychiatric disorders on their later life [26]. Yu *et al.*, [27] found a significant decrease in catalase and glutathione reductase activities in the liver although there were no obvious signs of maternal toxicity at any dose level, but the number of the nonviable embryos was significantly increased in single dose more than 20mg/kg AgNPs. So, many studies showed that toxicity of AgNPs have been associated with increased generation of ROS and oxidative stress in general [28].

## Conclusion

Silver nanoparticles can pass to the fetus's blood brain barrier of brain and disrupt the tight junction and cause more dilatation of micro porous which cause easy passage of this small size nano metal to the embryos during embryogenesis. AgNPs at low concentration 2mg/kg/day and higher concentration

20mg/kg/day can produce much histological toxicity to the embryos hindbrain and cerebellum when administrated to the dams during pregnancy period.

### Acknowledgement

I would like to thanks biotechnology research center, AL- Nahrain University, Baghdad, Iraq for help me in animal collection and special thanks to professor Dr. Mohamed jaweed, the histopathologist in the college of veterinary medicine in university of Baghdad, whom is examine my histological section for this study.

### References

1. Gomes, M.G., Dreier, J., Brewer, J., Martins, S., Brandl, M. and Sarmiento, B. **2016**. A new approach for a blood-brain barrier model based on phospholipid vesicles: Membrane development and siRNA-loaded nanoparticles permeability. *J. of Membrane Science*. **503**: 8–15
2. Bhaskar, S. F., Tian, T., Stoeger, W., Kreyling, J. M. de la Fuente, V. Grazu, P., Borm, G., Estrada, V., Ntziachristos, D. and Razansky **2010**. Multifunctional Nanocarriers for diagnostic, drug delivery and targeted treatment across blood-brain barrier: perspectives on tracking and neuroimaging. *Part Fibre Toxicol*. **7**: 3
3. Prakash, P.J., Royana, S., Sankarsan, P., Rajeev, S. **2017**. The Review of Small Size Silver Nanoparticle Neurotoxicity: A Repeat Study. *J. Cytol. Histol*, **8**: 468.
4. Scott, J. A., Hamzelou, K. S., Rajagopalan, V., Habas, P. A., Kim, K., Barkovich, A. J. **2012**. 3D morphometric analysis of human fetal cerebellar development. *Cerebellum*. **11**(3):761–70
5. Tam, E. W. **2013**. Potential mechanisms of cerebellar hypoplasia in prematurity. *Neuroradiology*. **55**(2):41–46
6. Strata, P. **2015**. The emotional cerebellum. *Cerebellum*. Advance online publication.
7. Leto, K., Arancillo, M. Becker, E. B., Buffo, A. Chiang, C., Ding, B. et al. **2015**. Consensus paper: cerebellar development. *Cerebellum*. PubMed PMID: 26439486. Pubmed Central PMCID: PMC4846577.
8. Rivero, P. J., Urrutia, A., Goicoechea, J. and Arregui, F. J. **2015**. Nanomaterials for functional textiles and fibers. *Nanoscale Res Lett*. **10**:501
9. Pardridge, W. M. **2016**. CSF, blood-brain barrier, and brain drug delivery. *Expert Opin. Drug Deliv*. **6**(1).
10. Simkó, M. and Olof Mattsson, M. **2014**. Interactions Between Nanosized Materials and the Brain. *Current Medicinal Chemistry*. **21**: 4200-4214.
11. Ypsilantis, P., Deftereos, S., Prassopoulos, P. and Simopoulos, C. **2009**. Ultrasonographic Diagnosis of Pregnancy in Rats. *J. of the American Association for Laboratory Animal Science*. **48**( 6)734–739
12. Charehsaz, M., Hougaard, K.S., Sipahi, H., Ekici, Asiye, I. D. Ç. Kaspar, Culha, M., Bucurgat, Ü. Ü. and Aydin, A. **2016**. Effects of developmental exposure to silver in ionic and nanoparticle form: A study in rats. *DARU. J. of Pharma. Sciences*. **24**: 24
13. Allen, D.C. and Cameron, R. I. **2004**. *Histopathology specimens: clinical, pathological and laboratory aspects*, London.: Springer
14. Dănilă, O., Berghian, A.S., Dionisie, V., Gheban, D., Olteanu, D., Tabaran, F., Baldea, I., Katona, G., Moldovan, B., Clichici, S., David, L. and Filip, G.H. **2017**. *The effects of silver nanoparticles on behavior, apoptosis and nitro-oxidative stress in offspring Wistar rats*. Nanomedicine (Lond.) Future Medicine Ltd.
15. Ballabh, P., Braun, A. and Nedergaard, M. **2004**. The blood–brain barrier: an overview-structure, regulation, and clinical implications. *Neurobiol Dis*. **16**(1): 1–13
16. Song, B., Liu, J., Feng, X., Wei, L. and Shao, L. **2015**. A review on potential neurotoxicity of titanium dioxide nanoparticles. *Nanoscale Research Letters*. **10**: 342
17. Liu, J. **2013**. Passive tumor targeting of renal-clearable luminescent gold nanoparticles: long tumor retention and fast normal tissue clearance. *J. Am. Chem. Soc*. **135**: 4978–4981.
18. Lin, H. C., Huang, C. L., Huang, Y. J., Hsiao, H. L., Yang, C.W. and Chuang, C.Y. **2016**. Transcriptomic gene-network analysis of exposure to silver nanoparticle reveals potentially neurodegenerative progression in mouse brain neural cells. *Toxicol. In Vitro* **34**: 289–299.
19. Paxinos, G. and Watson, C. **2007**. *The rat brain in stereotaxic coordinates*. Academic Press, New York

20. Hami, J., Vafaei-nezhad, S., Ghaemi, K., Sadeghi, A., Ivar, G., Shojae, F. and Hosseini, M. **2016**. *Stereological study of the effects of maternal diabetes on cerebellar cortex development in rat*. Springer Science+Business Media New York
21. Singh, R.P. and Ramarao, P. **2012**. Cellular uptake, intracellular trafficking and cytotoxicity of silver nanoparticles. *Toxicol. Lett*, **213**(2): 249–259.
22. Philbrook, N. A., Winn, L. M., Afrooz, ARMN, Saleh, N.B., Walker, V.K. **2011**. The effect of TiO<sub>2</sub> and Ag nanoparticles on reproduction and development of *Drosophila Melanogaster* and CD-1 Mice. *Toxicol. Appl. Pharmacol*, **257**: 429–436.
23. Prasek, M., Sawosz, E., Jaworski, S., Grodzik, M., Ostaszewska, T., Kamaszewski, M., Wierzbicki, M. and Chwalibog, A. **2013**. Influence of nanoparticles of platinum on chicken embryo development and brain morphology. *Nanoscale Research Letters*, **8**: 251.
24. Wu, J., Yu, C., Tan Y. *et al.* **2015**. Effects of prenatal exposure to silver nanoparticles on spatial cognition and hippocampal neurodevelopment in rats. *Environ. Res.* **138**: 67–73.
25. Di Bona, K.R., Xu, Y., Ramirez, P.A., DeLaine, J., Parker, C., Bao, Y. *et al.* **2014**. Surface charge and dosage dependent potential developmental toxicity and biodistribution of iron oxide nanoparticles in pregnant CD-1 mice. *Reprod. Toxicol*, **50**: 36–42.
26. Louboutin, J. P. and Strayer, D.S. **2013**. Relationship between the chemokine receptor CCR5 and microglia in neurological disorders: consequences of targeting CCR5 on neuroinflammation, neuronal death and regeneration in a model of epilepsy. *CNS Neurol. Disord-Drug Targets*, **12**(6): 815–829.
27. Yu, W.J., Son, J. M., Lee, J., Kim, S. H., Lee, I.C., Baek, H.S *et al.* **2014**. Effects of silver nanoparticles on pregnant dams and embryo-fetal development in rats. *Nanotoxicolo.* **8**: 85-91.
28. Ebabe, E. R., Gaillet, S., Vide, T., Romain, C., Lauret, C. and Netal, R. **2013**. dietary exposure to silver nanoparticles in Sprague-Dawely rats: effect on oxidative stress and inflammation. *Food chem. Toxicol*, **60**: 297-301.